

Frequency and Outcome of isolated zygomatic arch fractures (IZAF) in Road traffic accident (RTA) patients

Sahar Saeed¹, Ahmad Khan¹, Junaid Ahmad¹, Muneesh Kumar¹, Zohaib Nasar Khan¹ and Suneela Inayat¹

¹ Department of Oral and Maxillofacial Surgery, Mardan Medical Complex, Mardan Pakistan

ABSTRACT

Background: The zygomatic arch plays a key role in maintaining midfacial structure and aesthetics. Although isolated zygomatic arch fractures (IZAFs) represent only 5–10% of zygomaticomaxillary complex injuries, they can result in significant functional impairment and aesthetic deformity. This study aimed to evaluate the frequency and clinical outcomes of IZAFs in patients involved in road traffic accidents (RTAs) at a tertiary care hospital in Mardan Khyber Pakhtunkhwa Pakistan.

Methods: A prospective observational study was conducted over six months from August 2024 to Feb 2025 at the Department of Oral and Maxillofacial Surgery, Mardan Medical Complex. A total of 145 patients with IZAFs confirmed by computed tomography CT scan were enrolled using non-probability consecutive sampling. The data were collected regarding the demographic characteristics and clinical presentation (including swelling, cosmetic deformity, trismus, and facial nerve weakness. Patients were followed at 1- and 3-months post-treatment. The outcome measures were evaluated based on mouth opening improvements (interincisal distance), facial contour symmetry restoration, and recovery of facial nerve function.

Results: The mean age of the cohort was 30 ± 8 years. RTAs accounted for approximately 90% of the cases. All patients experienced pain at presentation, 60% had facial swelling, 40% exhibited trismus, 35% demonstrated cosmetic deformity, and 15% showed facial nerve weakness. Following treatment, the mean interincisal distance improved to 35 ± 4 mm at 1 month and 45 ± 3 mm at 3 months ($p < 0.001$), cosmetic deformity decreased to 10%, and facial nerve weakness reduced progressively from 15% at 4 weeks to 5% at 12 weeks ($p < 0.05$).

Conclusion: Prompt and appropriate management using minimally invasive techniques leads to improvements in mouth opening, facial contour restoration, and recovery of facial nerve function.

Keywords: Cosmetic Deformity, Facial Nerve Weakness, Isolated Zygomatic Arch Fracture, Maxillofacial Trauma, Road Traffic Accident, Trismus

This article may be cited as: Saeed S, Khan A, Ahmad J, Kumar M, Khan ZN, Inayat S. Frequency and Outcome of isolated zygomatic arch fractures (IZAF) in Road traffic accident (RTA) patients. Int J Pathol 23(4):330-7. <https://doi.org/10.59736/IJP.23.04.980>

CORRESPONDING AUTHOR

Dr. Suneela Inayat

Department of Oral and Maxillofacial Surgery, Mardan Medical Complex, Mardan
Email: sunilainayat@gmail.com

Introduction

The zygomatic arch is the most important component of the midface contributing to the maintenance of facial width and lateral projection. it is formed by the temporal process of the zygomatic bone and the

zygomatic process of the temporal bone (1). It acts as a support and bridge for the facial aesthetics and essential muscular attachments of the face. Because of its prominent position it is exposed to high-energy trauma, especially those involved in road traffic accidents (RTAs) (2).

The zygomatic arch can result in isolated fractures in 5–10% of all zygomaticomaxillary complex (ZMC) fractures and have significant implications for facial function and aesthetics (3). The isolated zygomatic arch fracture's (IZAFs) clinical features include swelling, pain, and reduced opening of the mouth (trismus). In Addition to that, patients may present with flattening and depression over the affected area, associated with edema and ecchymosis of the affected area sometimes; it may extend into the buccal sulcus and the periorbital area (4). In severe cases of ZMC fractures, the facial nerve may be involved, leading to facial palsy, compounding the functional deficit (5). Although several international studies have described the mechanisms and clinical spectrum of zygomatic arch fractures, region-specific epidemiological data from Pakistan and South Asia remain scarce.

There is a strong link between the etiology of isolated arch fractures and RTAs, although falls, sports-related injuries, assaults, and workplace accidents also contribute to their occurrence. The most common fracture pattern is “greenstick” fracture, typically located approximately 1.5 cm posterior to the zygomatico-temporal suture. The Epidemiological data showed that these fractures are more frequent among males, particularly those in their second to third decades of life, most frequently involved in high-energy trauma and the biomechanical factors influencing the patterns of fracture (6,7).

Zygomatic arch fracture classification is multifactorial and includes factors such as the degree of bone displacement, the presence of coronoid impingement, the direction and magnitude of the injurious force, and overall fracture morphology (8). An isolated fracture of the zygomatic arch specifically tends to occur when a lateral force is directly applied to the midface (9). This mechanism also implicates the masseter and the temporalis muscles, which are intimately associated with the zygomatic arch (10). In some cases where the fracture involves the coronoid process, patients often experience severe limitations in mouth opening, further complicating both diagnosis and management (11).

The management of IZAFs is based on the degree of displacement of the fracture. In most cases of minimal displacement, conservative management is the treatment of choice. However, in the case of grossly displaced fractures, surgical intervention is often necessary. The most effective intervention is Open reduction and rigid fixation, but it carries many risks such as significant hemorrhages, facial nerve injuries, and scarring. As a result, the most favorable technique used these days is closed reduction. Among these, the Gillies temporal approach has emerged as a preferred method due to its ease of performance, minimal invasiveness, and decreased risk of postoperative complications. In this approach, a temporal hairline incision is inclined, and the elevator is placed between the fascia and the temporalis muscle to elevate and reposition the displaced zygomatic arch (12). The alternative technique most often used are Keen's intraoral approach, lateral coronoid, and percutaneous methods, which also in practice having its own risk and benefits (7,13).

The literature review showed that IZAFs have been associated with considerable morbidity (14). Systematic reviews showed that these fractures, though infrequent, and the presenting clinical features are swelling, pain, and trismus. For instance, one study reported that 100% of patients experienced pain, and swelling was observed in 60% and trismus in 40% of the cases (15). A comparative analysis showed that the patients who have undergone surgical management for IZAFs are more likely to present with complications, including neurological complication paresthesia, trismus, and zygomatic deformity as compared to those managed conservatively (16).

There is lack of local regional data in Pakistan and South Asia regarding the frequency, etiology and clinical outcomes of IZAFs. The aim of this study is to fill this gap so as to determine the frequency and outcomes of isolated zygomatic arch fractures (IZAFs) among road traffic accident patients, assessing mouth-opening improvement, restoration of facial contour, and recovery of facial nerve function. The findings of this study will add local evidence to the literature for optimizing maxillofacial trauma management.

Methods

The study design was prospective observational and was conducted at the Department of Oral and Maxillofacial Surgery, Mardan Medical Complex, Mardan Pakistan. The study duration was six months, from August 2024 to February 2025. The ethical approval was taken from the ethical review board of Bacha Khan College of Dentistry having ethical approval number 037BKCD dated 20 May 2023. The sample size was 145, which was calculated using an open Epi sample size calculator. The margin of

error was 8% with a 95% confidence interval (CI), and an estimated frequency of 40% for limited mouth opening (trismus). The sampling technique was non probability consecutive sampling.

Patients of any gender aged 18-60 years with isolated zygomatic arch fractures (IZAFs) treated within 2 to 60 days of injury, presenting with limited mouth opening (trismus) and cosmetic deformity. Patients with displaced isolated or combined zygomatic arch fractures, classified as Özyazgan Type 1-B (D) or Type 2-B (D) were also included in the study. Patients with associated fractures (such as cranial or maxillary fractures) alongside zygomatic arch fractures and patients with pre-existing facial asymmetry were excluded from the study.

Patients fulfilling the inclusion criteria were enrolled in the study after taking written informed consent. CT scan was used for the confirmation of diagnosis of zygomatic arch fractures. For the collection of data, a structured questionnaire was designed which included demographic data and clinical data regarding the presence of swelling, pain, trismus, facial nerve weakness, and cosmetic deformity. Trismus was measured as interincisal distance using a vernier caliper, and facial nerve weakness was assessed with the House-Brackmann grading system. All the patients were followed for a period of three months; the outcomes such as improvement in mouth opening, resolution of facial nerve weakness, and restoration of facial contour symmetry were closely checked at each follow-up. Out of the 145 enrolled patients, 133 (91.7%) completed the full three-month follow-up, while the remainder were lost to follow-up.

Data analysis was done using IBM SPSS version 26. The quantitative variables were

expressed as mean \pm standard deviation (SD), while qualitative variables were expressed as frequencies and percentages. The Shapiro-Wilk test was used for checking the normality of data distribution. Chi-square test or Fisher's exact was used for categorical comparisons. A p-value of ≤ 0.05 at 95% Confidence intervals was considered statistically significant. Additional statistical measures such as Odd Ratio was calculated to assess the association between the fracture type and clinical outcomes, intraclass correlation coefficient was applied for verification of inter-rater reliability of facial-nerve grading and mouth-opening measurements between observers.

Results

A total of 145 patients with isolated zygomatic arch fractures (IZAFs) were analyzed. The majority of the patients were young males (mean age = 30 ± 8 years; 80% male), and road traffic accidents (RTAs) accounted for 90% of cases. Significant postoperative improvements were observed in mouth opening, facial contour symmetry, and facial-nerve recovery ($p < 0.05$ for all). All these findings collectively indicate that the applied management protocols were effective in achieving both functional and aesthetic recovery. Table 1 summarizes the demographic characteristics of the patients.

Table 1. Demographic Characteristics

Variable	Value
Total Patients	145
Mean Age (years)	30 ± 8 (Range: 18–60)
Gender – Male	80% (116 patients)
Gender – Female	20% (29 patients)
Cause (RTAs)	90% of cases

The most common presenting symptoms in the participants were pain, facial swelling, limited mouth opening, or trismus. The mean

interincisal distance was 25 ± 5 mm. Cosmetic deformities were present in 35% of the patients. The Facial nerve weakness was noticed in 15% of the patients.

Table 2. Clinical Presentation and Outcomes of IZAF Patients (n=145)

Clinical Parameter	Baseline	1 Month Follow-up	3 Months Follow-up	p-value
Pain	145 (100%)	–	–	–
Facial Swelling	87 (60%)	–	–	–
Limited Mouth Opening (Trismus)	58 (40%)	–	–	–
Mean Interincisal Distance	25 ± 5 mm	35 ± 4 mm	45 ± 3 mm	<0.001
Cosmetic Deformity	51 (35%)	–	15 (10%)	<0.05
Facial Nerve Weakness	22 (15%)	12 (8%)	8 (5%)	<0.05

Sub-Section A: Mouth Opening and Cosmetic Deformity

Parameter	Baseline	1 Month Follow-up	3 Months Follow-up	p-value
Mean Interincisal Distance	25 ± 5 mm	35 ± 4 mm	45 ± 3 mm	<0.001
Cosmetic Deformity (%)	51 (35%)	–	15 (10%)	<0.05

Sub-Section B: Facial Nerve Function

Time Point	Facial Nerve Weakness (%)	p-value
4 Weeks Post-op	22 (15%)	<0.05
8 Weeks Post-op	12 (8%)	
12 Weeks Post-op	8 (5%)	

Following the treatment there was significant improvements across all measured outcomes. The mean interincisal distance, indicative of mouth opening, increased progressively from 25 ± 5 mm at presentation to 35 ± 4 mm at the 1month follow-up, and 45 ± 3 mm at 3 months follow-up postoperatively ($p < 0.001$).

Over the follow-up period cosmetic outcomes also showed considerable improvement. The cosmetic deformity which was 35% at baseline decreased to 10% at 3 months post-treatment. This reduction reflects a significant restoration of facial symmetry and improved patient satisfaction.

The facial nerve function also showed a progressive recovery over the follow-up period. At 4 weeks post-treatment, 15% of patients showed some degree of facial nerve weakness, which decreased to 8% at 8 weeks and further decreased to 5% at 12 weeks ($p < 0.05$).

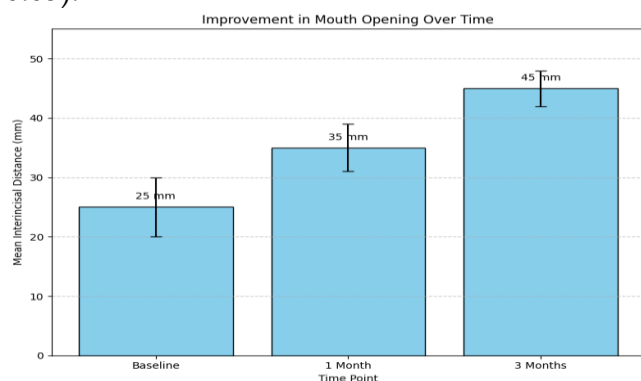


Figure 1: Improvement in Mouth Opening Over Time among Patients with Isolated Zygomatic Arch Fractures (IZAFs).

These statistically significant improvements across multiple parameters ($p < 0.05$) confirm the efficacy of the treatment approaches used for IZAFs. All these results demonstrate that the treatment approach employed for isolated zygomatic arch fractures is effective in enhancing both functional outcomes such

as improved mouth opening and aesthetic outcomes, including the restoration of facial symmetry, while also facilitating recovery of facial nerve function.

Discussion

Our study provides valuable local evidence on the functional and aesthetic recovery following isolated zygomatic arch fractures (IZAFs) in patients involved in road traffic accidents (RTAs). Our results showed significant improvements in mouth opening and facial symmetry and a progressive recovery of facial nerve function over the follow up period. These findings are consistent with previous reports in the literature who also observed comparable improvements in mouth-opening and facial symmetry following minimally invasive closed reduction techniques.(17).

The mean age of the study participants in our study was 30 ± 8 years with an 80% male predominance aligns with previous studies in which the young males were identified as the primary victims of high-energy trauma leading to IZAFs(18). The predominance of RTAs accounts for 90% of cases reinforces the observation that high-impact forces are the most common etiological factor in these injuries(19). Most common clinical presentation in our patients were pain, facial swelling and trismus, which are in agreement with the clinical findings reported in previous studies (20).

There was marked improvement in the opening of mouth, as evidenced by the increase in mean interincisal distance from 25 mm to 45 mm over a three-month period, which highlighted the effectiveness of the closed reduction techniques. This increase closely parallels the 18- to 22-mm improvement range documented by previous literature, confirms that early intervention yields predictable functional recovery. This

outcome is in agreement with the findings reported by previous research, which noted significant functional recovery after surgical intervention for the management of IZAFs(21). The reduction in cosmetic deformity from 35% at baseline to 10% at 3 months underscores the benefit of prompt treatment in restoring facial symmetry, this finding further supports the outcomes observed in previous studies. This reduction aligns with the 32 % improvement reported by other studies highlighting the role of prompt reduction in restoring facial contour and patient satisfaction(22). The progressive decrease in the incidence of facial nerve weakness from 15% at 4 weeks to 5% at 12 weeks are also in consistent with the trends in previous studies(23).

All these findings highlighted the critical importance of early diagnosis and intervention for the management of IZAFs. This study reinforces the prominent role of closed reduction techniques, including the Gillies temporal approach, for achieving significant improvements in both functional and aesthetic outcomes. The recovery of the facial nerve function further suggests that the complications involved with surgical intervention can be minimized through timely intervention. Adding this evidence into trauma-care protocols could reduce morbidity, operative time, and postoperative complications in regional maxillofacial units.

Limitations & Future

Recommendations

There are several limitations in our study including cross-sectional design, single-centered study and short follow-up period of three months. Cost-effectiveness analyses and multicenter collaborations across Pakistan and South Asia would help develop standardized treatment guidelines tailored to regional trauma patterns.

Conclusion

Our study demonstrates that IZAFs primarily resulting from high-energy road traffic accidents are associated with significant functional and aesthetic impairments. Prompt and appropriate management using minimally invasive techniques leads to improvements in mouth opening, facial contour restoration, and recovery of facial nerve function. These findings provide essential local evidence to guide future clinical practice and policymaking in the management of maxillofacial trauma.

Funding Sources: Nill

Conflict of interest: Nill

References

1. Duan J, Cong LY, Luo CE, Luo SK. Clarifying the anatomy of the zygomatic cutaneous ligament: its application in midface rejuvenation. *Plast Reconstr Surg.* 2022 Feb 1;149(2):198e–208e. doi: 10.1097/PRS.00000000000008716.
2. Bergeron JM, Hohman MH, Raggio BS. Zygomatic arch fracture. In: StatPearls [Internet]. Treasure Island (FL): StatPearls Publishing; 2025 Jan–. 2024 Jan 26.
3. Jones CM, Schmalbach CE. Zygomaticomaxillary fractures. *Facial Plast Surg Clin North Am.* 2022 Feb;30(1):47–61. doi: 10.1016/j.fsc.2021.08.004.
4. Singh V, Chhikara N, Jajodia N. Zygomaticomaxillary complex fractures. In: *Maxillofacial Trauma: A Clinical Guide.* Singapore: Springer Singapore; 2021 May 3. p. 293–310.
5. Cil Y. Treatment of isolated zygomatic arch fractures with the Gillies method. *Eur J Plast Surg.* 2023;46(4):511–4.
6. Obimakinde OS, Olajuyin OA, Akinbade AO, Ojo KO, Ibidun CO. Zygomatic complex fractures in a Nigerian tertiary hospital: an update on pattern of

- presentation and care. *Niger Stethoscope*. 2023 Jun 30;5(1):63–76.
7. Vos LM, Huddleston Slater JJR, Stegenga B. Arthrocentesis as initial treatment for temporomandibular joint arthropathy: a randomized controlled trial. *J Craniomaxillofac Surg*. 2014;42(5): e134–9.
 8. Valdés Reyes JM, Zapata Ocampo S. Functional classification of isolated zygomatic arch fracture: new proposal. *J Craniofac Surg*. 2021 Mar-Apr;32(2):757–8. doi: 10.1097/SCS.00000000000006938.
 9. Frosolini A, Benedetti S, Gennaro P, Gabriele G. Comment on "Proposal for a modified classification of isolated zygomatic arch fractures". *Arch Craniofac Surg*. 2023 Jun;24(3):143–4. doi: 10.7181/acfs.2023.00192.
 10. Wang MR, Chin MG, McIntire DR, Chang K, Zhao L, Kwan DK. The association of fracture displacement and surgical intervention in isolated zygomatic arch fractures. *J Oral Maxillofac Surg*. 2025 Jan 20;83(5):565–75. doi: 10.1016/j.joms.2025.01.006.
 11. Jung S, Yoon S, Nam SH. Proposal for a modified classification of isolated zygomatic arch fractures. *Arch Craniofac Surg*. 2022;23(3):111–8.
 12. Tiwari M, Gupta M, Roy S. Analysis of Gillies temporal approach vs Towel Clip method for reduction of zygoma fractures. *Oral Maxillofac Surg*. 2024 Dec;28(4):1643–51.
 13. de Moura AM, Marinho DR, de Matos BM. Reduction of zygomatic arc fracture by intraoral access. *Multidiscip Sci J*. 2022;4(2).
 14. Gentile MA, McKinlay AA, Stires SA. Pediatric maxillary and zygomatic fractures. In: *Pediatric Maxillofacial Trauma*. Cham: Springer International Publishing; 2020. p. 115–43.
 15. Karşıcı S, Balaban E. The effect of preoperative low-level laser therapy on pain, swelling, and trismus associated with mandibular third molar extraction. *BMC Oral Health*. 2025;25(1):306.
 16. Ling XF, Yew CC, Mohd Nazri SB, Tew MM. Unilateral zygomatic complex fracture - a comparison between nonsurgical treatment and surgical treatment. *J Craniofac Surg*. 2021 Oct 1;32(7):e627–30. doi:10.1097/SCS.00000000000007606.
 17. Wang HD, Dillon J. Contemporary management of zygomaticomaxillary complex fractures. *Semin Plast Surg*. 2021 Nov;35(4):256–62.
 18. Jones CM, Schmalbach CE. Zygomaticomaxillary fractures. *Facial Plast Surg Clin North Am*. 2022 Feb;30(1):47–61. doi: 10.1016/j.fsc.2021.08.004.
 19. Abbas Z, Imran MB, Khalil F, Khan MA. Zygomatic complex fractures in patients with oral and maxillofacial trauma: prevalence and causes at a tertiary care center. *Med Forum Mon*. 2024;35(10).
 20. Wang MR, Chin MG, McIntire DR, Chang K, Zhao L, Kwan DK. The association of fracture displacement and surgical intervention in isolated zygomatic arch fractures. *J Oral Maxillofac Surg*. 2025;83(5):565–75. doi: 10.1016/j.joms.2025.01.006.
 21. doi: 10.1016/j.joms.2025.01.006.
 22. Devakumari S, Dominic N, Vijhayapriya T, Dinesh DS, Devameena S. Modified temporal incision for the management of zygomatic arch fractures: a retrospective study for 7 years. *Craniofac Trauma Reconstr*. 2021;15(1):12–20. doi: 10.1177/1943387521989550.
 23. Saponaro G, Moro A, Todaro M, Gasparini G, Perquiti F, Ascani G, et al. Aesthetic approaches to zygomatic fracture management: achieving optimal outcomes

with minimal scarring. J Craniofac Surg. 2025;36(1):279.

24. Rahman S, Roy ID, Kumari P. Recovery of neurosensory deficit in zygomatic complex

fracture: a prospective study. J Dent Def Sect. 2022;16(2):119.

HISTORY	
Date received:	22-08-2025
Date sent for review:	09-10-2025
Date received reviewers' comments:	22-10-2025
Date received revised manuscript:	08-11-2025
Date accepted:	09-11-2025

CONTRIBUTION OF AUTHORS	
AUTHOR	CONTRIBUTION
Conception/Design	SS, AK, SI
Data acquisition, analysis and interpretation	SS, AK, JA, MK, ZNK
Manuscript writing and approval	JA, MK, ZNK, SI
All the authors agree to take responsibility for every facet of the work, making sure that any concerns about its integrity or veracity are thoroughly examined and addressed.	