

Patterns of Eosinophilia in Cardiac Patients and its Association with Endomyocardial Disease in a Tertiary Care Hospital at Peshawar

Rashid Azeem¹, Abidullah², Syed Shahkar Ahmad Shah³, Saba Khan⁴, Shah Zeb⁵ and Ijaz Hussain⁶

^{1,4}Department of Pathology, Peshawar Institute of Cardiology (PIC), ^{2, 5, 6}Department of Cardiology, (PIC),

³Department of Cardiac surgery (PIC).

ABSTRACT

Introduction: Eosinophilia, which can be categorized as mild, moderate and severe form on the basis of increasing eosinophil counts, might be responsible for a wide range of cardiac manifestations, varying from a simple myocarditis to a severe state like endomyocardial fibrosis. Eosinophils are involved in the pathogenesis of a variety of cardiovascular disorder like Löffler endocarditis, eosinophilic granulomatosis with polyangiitis (EGPA) and hyper eosinophilic syndrome (HES).

Objectives: To determine the patterns of eosinophilia in cardiac patients and its association with endomyocardial diseases in eosinophilic patients

Material and Methods: This cross-sectional analytical study was conducted in hematology Department of Peshawar institute of Cardiology after approval from hospital ethical and research committee. All 70 patients were subjected to detailed history and clinical examination. Investigation like CBC, Chest X-ray, ECG, Echo, Angiography findings were used to monitor patient's clinical status. Data is analyzed using SPSS version 25 and MS Excel

Results: Out of 70 patients in our study, a total of 66 patients (94%) shows evidence of cardiac manifestations. In our study we have observed a number of abnormal ECG patterns like T wave changes, loss of R wave, sinus bradycardia with LVH strain and ST wave abnormality. Abnormal echocardiographic findings were observed like valvular abnormalities (in 45.7%), RWMA abnormalities (in 5.7%), isolated ventricular dysfunction (in 21.4%). We further noted abnormal coronary angiography findings ranging from single vessel to multi vessel occlusions. Chi square test was applied showing significant P value of 0.001

Conclusions: Increased eosinophilic count as a laboratory parameter in cardiac patients may be a sign of endomyocardial damage helping the cardiologist to intervene more aggressively than routine approach.

Key Words: Eosinophilia, Endomyocardial fibrosis, cardiac patients

Introduction

Eosinophils are myeloid cells with red-orange staining granules. They are released from the bone marrow under the influence of many cytokines including IL-3 and IL-6 GM-CSF, circulates in the blood for about 8-18 hours and then resides in the tissue. Normal blood eosinophilia count is 0 to 500 cells/mm³ i.e. less than 5% of total white cell count.¹

When the number of eosinophils exceeds 5% of the total WBC count it is referred as Eosinophilia which can be categorized as Mild Eosinophilia (0.5% to 5%) Moderate Eosinophilia (5% to 15%) and Severe Eosinophilia >15% of total WBC count.² Endocarditis and myocarditis are inflammatory conditions of endocardium and myocardium caused by infiltration of inflammatory cells into the cardiac tissue and this detailing the cardiac function. Infection (viral, bacterial, fungal, protozoal), drugs, toxic substances and Immune mediated diseases are the most common among the extensive causes of cardiomyopathies.³ Eosinophil has a great role in the pathogenesis of endo-myocardial disorder and is involved in parasite-mediated, drug induced and hypersensitivity

CORRESPONDENCE AUTHOR

Dr. Saba Khan

Department of Pathology
Peshawar Institute of Cardiology, Peshawar
Email: saba.khan@pic.edu.pk

mediated myocarditis. There are three phases of eosinophilic heart disease. The first stage is due to infiltration of eosinophils in the cardiac tissues and subsequently leads to myocardial necrosis due to release of the granular proteins (MBP, EPO and ECP). This phase is usually presented as eosinophilic myocarditis. Second phase, represented by thrombus formation is associated with increased levels of circulating thrombin and thus forms a hypercoagulable state. This is due to impaired formation of the thrombomodulin-thrombin complex and abnormal binding of eosinophilic cation proteins with thrombomodulin. The final phase of EM is represented by fibrotic scarring. Eosinophils have the potential to promote fibroblast activation, proliferation, and extracellular fibrotic deposition and as a result of this cardiac endothelium and valves become fibrotic and thickened, resulting in Löffler's fibroplastic endocarditis.⁴ Eosinophils are involved in the pathogenesis of a variety of cardiovascular disorder like Löffler endocarditis, eosinophilic granulomatosis with polyangiitis (EGPA) and hyper eosinophilic (HES)⁵ Among them HES carries an incidence rate b/w 48% and 75% and is the main causes of cardiac mortality and morbidity due to eosinophilia involvement.⁶ In an another publication cardiac complications occurred in ~20-50% of patients with prolonged high eosinophil counts and hyper eosinophilic syndrome and eosinophilic granulomatosis with polyangiitis were found to be a major cause of mortality.⁷ However, it is observed that antiplatelet drug like aspirin can also cause eosinophilia.⁸

The aim of this study is to determine the frequency of eosinophilia in cardiac patients and to ascertain the evidence of endomyocardial diseases in eosinophilic patients in a cardiology institution as there is limited data available in this regard both nationally and internationally. Moreover, by assessing the exact figure especially diagnostic methods like Computed tomography (CT), Angiography, Echocardiography (ECG), Cardiac Echo and Cardiac Magnetic Resonance Imaging (MRI) and even gold the standard methods like endo-myocardial biopsies could be of help in the definitive diagnosis and further management of patients thus avoiding further cardiac damage and providing a better quality of life for the cardiac patients. Increased eosinophilic count as a laboratory parameter in cardiac patients may be a sign of endomyocardial damage which will further help cardiologist to intervene more aggressively then

routine approach in a cardiac patient.

Material and Methods

This cross sectional analytical study was conducted in hematology Department of Peshawar institute of Cardiology after approval from hospital ethical and research committee. All patients were subjected to detailed history and clinical examination. Demographic (Age, Gender) and clinical information e.g. duration and severity of disease was also obtained through a Proforma. Investigation like CBC, Chest X-ray, ECG, Echo, Angiography findings were used to monitor patient's clinical status. Study duration was 6 months (from September 2021 till February 2022) and study data is analyzed using SPSS version 25, Mean and standard derivation was calculated for numerical variables such as age, gender, while frequency and percentages are calculated for categorical variables. Data is presented in the form of tables and charts using MS Excel.

Sample size was calculated using WHO sample size calculator;

- Confidence interval: 95%
- Margin of error: 5%
- Prevalence: 5%
- Estimated population size: 35 million
- Sample Size: 70

Both pediatric and adult cardiology patients presenting with eosinophilia were included in the study. Patients with history of known allergy, autoimmune disease and regular use of aspirin are excluded from the study

Operational Definitions

Mild eosinophilia: Eosinophils making 6% to 10% of total WBC count (AEC 600-1000).

Moderate eosinophilia: Eosinophils making >10% to 20% of total WBC count (AEC >1000-2000).

Severe eosinophilia: Eosinophils making >20% of total WBC count (AEC >2000).

Results

Out of 70 patients, 48 (69%) were males and 22 (31%) were females. Chi square test on gender was applied P value was 0.023. Patients were divided into 4 age groups, Group 1 (1-10 years), Group 2 (11-20 years), Group 3 (21-40 years) and Group 4 (>40 years) as shown in (Figure 1) Chi square test was applied on age showing P value of 0.05. Mean and SD of age was 43.44 and 21.793 respectively.

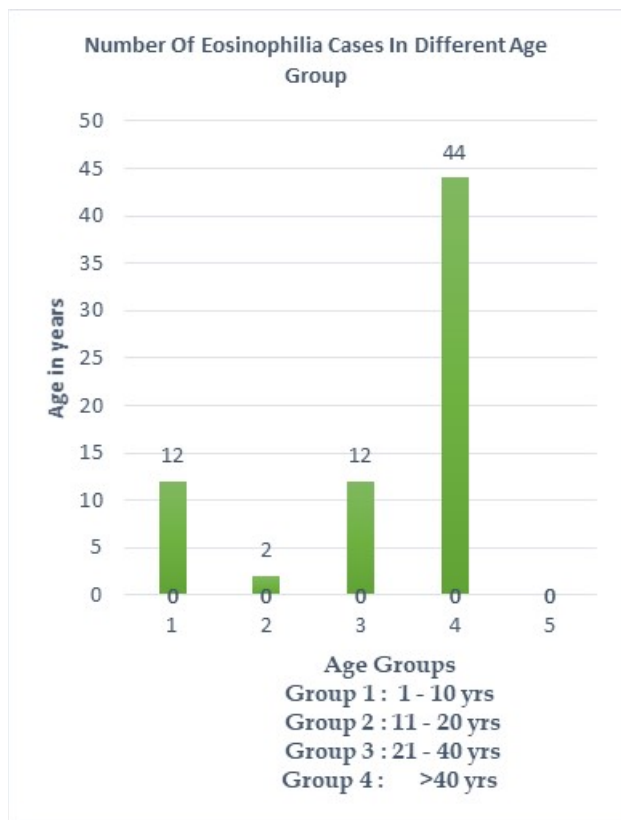


Figure: 1

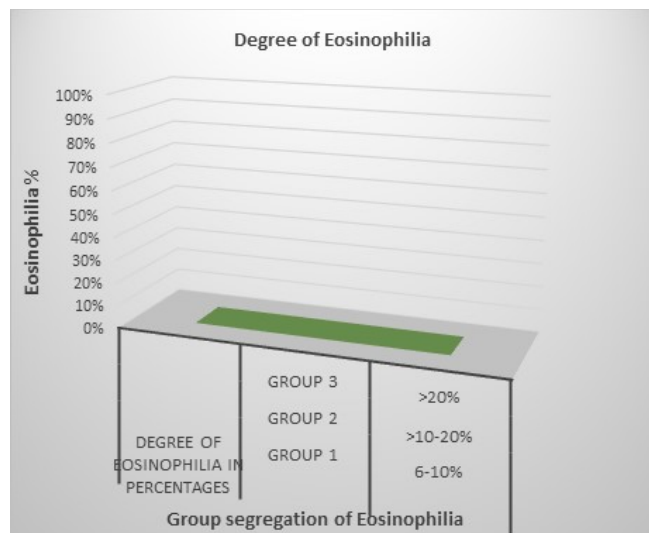


Figure :2 On the basis of severity, we divided eosinophilia into 3 groups that is m Group 1 mild eosinophilia (6% to 10%) Group 2 moderate (>10% to 20%) and Group 3 severe eosinophilia >20% of total WBC count (Figure 2). Mean and SD of eosinophil count was 11.85 and 3.877 respectively. A major portion of our sample size was cases of moderate eosinophilia however there was statistically non-

significant association of severity of eosinophilia with age and gender.

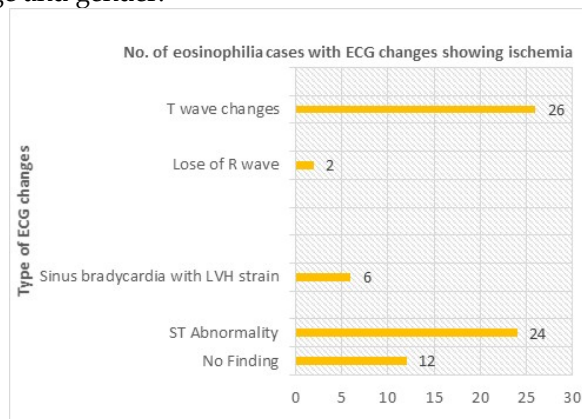


Figure 3

Pvalue:0.001

Figure 3 shows abnormal ECG findings in cardiac patients presenting with eosinophilia. Out of 70 patients, 26 (37.1%) presented with T wave changes, 2 (2.8%) with loss of R wave, 6 (8.5%) with sinus bradycardia with LVH strain, 24 (34.2%) with ST wave abnormality and 12 (17.1%) presented with no ECG findings at all. Chi square test was applied on ECG findings showing P value of 0.001.

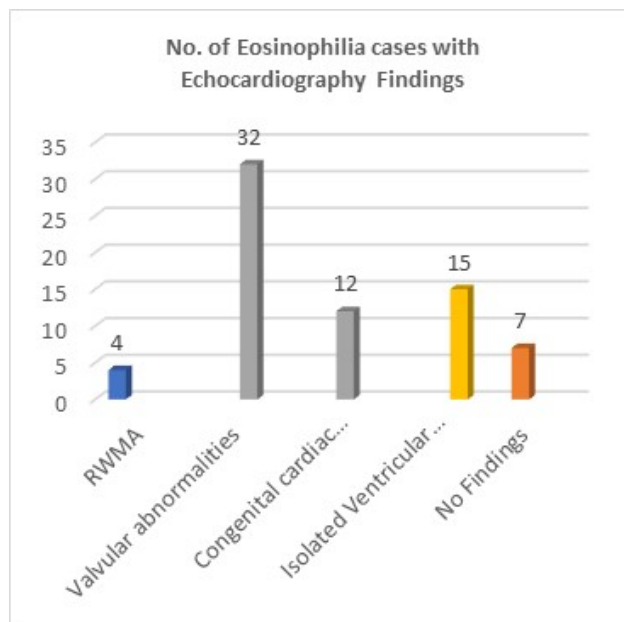


Figure 4 shows different abnormal echocardiographic findings were observed in the patients like valvular abnormalities in 32 (45.7%) patients, Regional wall motion abnormality (RWMA) abnormalities in 4 (5.7%) cases, congenital cardiac abnormalities in 12 (17.1%) patients, isolated ventricular dysfunction in 15 (21.4%) patients and 7 (10%) patients without any

finding in echocardiography. Chi square test was applied on echocardiography findings and showing P value of 0.001.

In patients with eosinophilia we observed single vessel, double vessel and triple vessel disease in 11 (15.7%), 14 (20%) and 10 (14.2%) cases respectively on angiography while in 9 (12.8%) cases the findings were normal and in 26 (37.1%) cases angiography was not performed at all (Figure 5) Chi square test was applied on angiography findings showing 0.021. In total of 70 patient presented with eosinophilia of varying severity, evidence of endomyocardial disease was found in 44 (62.8%) patients based on ECG, in 45 (64.2%) cases based on echocardiography and in 32 (45.7%) cases based on angiography. Combine evidence of endomyocardial disease based on ECG, Echocardiography and Angiography was found in 66 patients (94%) while in 4 (6%) patients no such evidence was noted, Chi square test was applied showing significant P value of 0.001(Figure6)

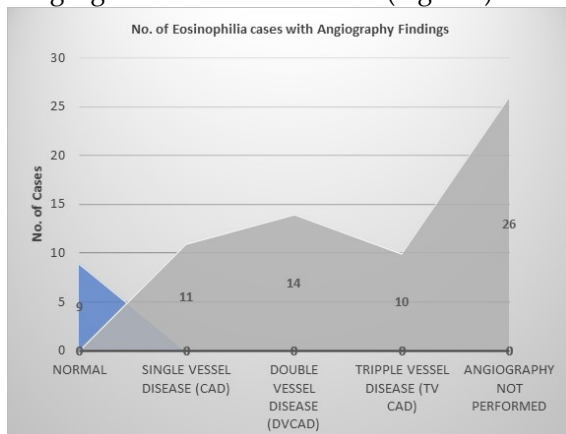


Figure :5
P value: 0.021

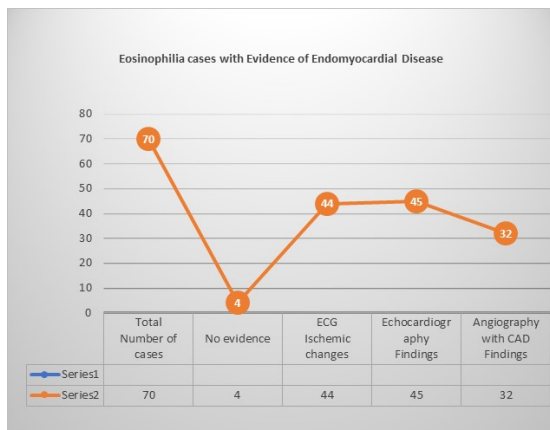


Figure: 6
P value: 0.001

Discussion

Eosinophilia, which can be categorized as mild, moderate and severe form on the basis of increasing eosinophil counts, might be responsible for a wide range of cardiac manifestations, varying from a simple myocarditis to a severe state like endomyocardial fibrosis.⁹ Among the wide range of cardiac injuries progressive restrictive cardiac disease was found to be the major cause of mortality and morbidity.¹⁰

Out of 70 patients in our study, a total of 66 patients (94%) shows evidence of cardiac manifestations (Endomyocardial disease). These cardiac diseases associated with eosinophilia can be detected by using various diagnostic methods. In our study we have observed a number of abnormal ECG patterns in cardiac patients presenting with eosinophilia like T wave changes, loss of R wave, sinus bradycardia with LVH strain and ST wave abnormality. In comparison ECG findings were often abnormal, mostly demonstrating ST-T segment abnormalities but neither sufficiently specific nor sensitive for myocarditis.¹¹ The additional ECG findings observed in our study might be due to other cardiac diseases apart from those caused by eosinophilic myocarditis.

Various studies show a wide range of echocardiographic features in patients with Eosinophilic Myocarditis varying from a severe left ventricular systolic dysfunction to almost normal echocardiographic findings, significant endomyocardial and valvular involvement (posterior mitral valve leaflet involvement in 20%, tricuspid involvement in 10%), left ventricular dysfunctions(LV hypertrophy in 10%, LV dilatation in 14%, LV apical thrombus in 24%), as well as findings like restrictive cardiomyopathy were also observed as endomyocardial scarring progresses.^{12,13,14}

Our study findings show similarity with these studies as similar abnormal echocardiographic findings were observed in our patients like valvular abnormalities (in 45.7%), RWMA abnormalities (in 5.7%), isolated ventricular dysfunction (in 21.4%) and in 10% patients a normal echocardiography. In should also be given special attention that eosinophilic myocarditis may simulate acute myocardial infarction and may present with similar echocardiographic findings and thus should be considered in patients with a history of allergies, even in the absence of significant eosinophilia in their blood complete picture.¹⁴

We further noted abnormal coronary angiography findings in cardiac patients with eosinophilia ranging from single vessel to multi vessel occlusions. Similar findings were observed in a study where coronary angiography showed coronary artery spasm, which was usually multi-focal, in a majority proportion (83%) of the patients.¹⁵ These similarities provide a strong evidence of the

cardiac vascular damage and occlusion as a result of thrombotic events which is explained in the 2nd phase of pathogenesis of endo myocardial damage as a result of eosinophilia.⁵

Conclusion

Eosinophilia can be a sign of cardiac diseases and this easy laboratory parameter can help the cardiologists and cardiac surgeon to detect early cardiac diseases by performing further cardiac diagnostic workup in these patients.

Recommendations

Patterns of eosinophilia in general population may also be studied in relation to undiagnosed cardiac diseases that will further give strength to hypothesis of relating eosinophilia with cardiac manifestations.

Conflict of Interest: Authors declare no conflict of interest.

Funding: No funding was received for this project

References

1. Sakula A. Henry Hyde Salter (1823-71): a biographical sketch. *Thorax*. 1985 Dec;40(12):887.
2. Chen YY, Khoury P, Ware JM, Holland-Thomas NC, Stoddard JL, Gurprasad S, Waldner AJ, Klion AD. Marked and persistent eosinophilia in the absence of clinical manifestations. *Journal of allergy and clinical immunology*. 2014 Apr 1; 133(4):1195-202.
3. Tschöpe C, Ammirati E, Bozkurt B, Caforio AL, Cooper LT, Felix SB, Hare JM, Heidecker B, Heymans S, Hübner N, Kelle S. Myocarditis and inflammatory cardiomyopathy: current evidence and future directions. *Nature Reviews Cardiology*. 2021 Mar; 18(3):169-93.
4. Kuchynka P, Palecek T, Masek M, Cerny V, Lambert L, Vitkova I, Linhart A. Current diagnostic and therapeutic aspects of eosinophilic myocarditis. *BioMed research international*. 2016 Oct;2016
5. Weller PF, Bubley GJ. The idiopathic hypereosinophilic syndrome. *Blood*. 1994 May 15;83(10):2759-79.
6. Zhong Z, Yang Z, Peng Y, Wang L, Yuan X. Diagnosis and treatment of eosinophilic myocarditis. *J Transl Autoimmun*. 2021 Sep

7. Diny NL, Baldeviano GC, Talor MV, Barin JG, Ong S, Bedja D, Hays AG, Gilotra NA, Coppens I, Rose NR, Čiháková D. Eosinophil-derived IL-4 drives progression of myocarditis to inflammatory dilated cardiomyopathy. *J Exp Med*. 2017 Apr
8. Szczeklik A, Stevenson DD. Aspirin-induced asthma: advances in pathogenesis and management. *Journal of Allergy and Clinical Immunology*. 1999 Jul 1;104(1):5-13.
9. Séguéla PE, Iriart X, Acar P, Montaudon M, Roudaut R, Thambo JB. Eosinophilic cardiac disease: molecular, clinical and imaging aspects. *Archives of cardiovascular diseases*. 2015 Apr 1;108(4):258-68.)
10. Solley GO, Maldonado JE, Gleich GJ, Giuliani ER, Hoagland HC, Pierre RV, Brown Jr AL. Endomyocardial disease with eosinophilia. *In Mayo Clinic Proceedings* 1976 Nov 1 (Vol. 51, No. 11, pp. 697-708).
11. A. L. P. Caforio, S. Pankuweit, E. Arbustini et al., "Current state of knowledge on aetiology, diagnosis, management, and therapy of myocarditis: a position statement of the European Society of Cardiology Working Group on Myocardial and Pericardial Diseases," *European Heart Journal*, vol. 34, no. 33, pp. 2636-2648, 2013.
12. S. R. Ommen, J. B. Seward, and A. J. Tajik, "Clinical and echocardiographic features of hypereosinophilic syndromes," *American Journal of Cardiology*, vol. 86, no. 1, pp. 110-113, 2000.
13. Davies J, Gibson DG, Foale R, Heer K, Spry CJ, Oakley CM, Goodwin JF. Echocardiographic features of eosinophilic endomyocardial disease. *Heart*. 1982 Nov 1;48(5):434-40
14. Galiuto L, Enriquez-Sarano M, Reeder GS, Tazelaar HD, Li JT, Miller Jr FA, Gleich GJ. Eosinophilic myocarditis manifesting as myocardial infarction: early diagnosis and successful treatment. *In Mayo Clinic Proceedings* 1997 Jul 1 (Vol. 72, No. 7, pp. 603-610). Elsevier.
15. Wong CW, Luis S, Zeng I, Stewart RA. Eosinophilia and coronary artery vasospasm. *Heart, Lung and Circulation*. 2008 Dec 1;17(6):488-96.

HISTORY	
Date received:	05-12-2022
Date sent for review:	10-12-2022
Date received reviewers comments:	03-01-2023
Date received revised manuscript:	07-01-2023
Date accepted:	24-03-2023

KEY FOR CONTRIBUTION OF AUTHORS:

- A. Conception/Study/Designing/Planning
- B. Active Participation in Active Methodology
- C. Interpretation/ Analysis and Discussion

CONTRIBUTION OF AUTHORS	
Author	Contribution
Rashid Azeem	A,B,C
Abidullah	A,C
Syed Shahkar Ahmad Shah	A,C
Saba Khan	A,B,C
Shah Zeb	A,C
Ijaz Hussain	A,C