

### Editorial Board

**Editor in Chief**

Anwar Ul Haque

**Managing Editors**

Nuzhat S. Khattak

**Editors**

Khalid Hassan

Nadeem Ikram

Micheal Hart (USA)

Javed Wazir (UK)

**Section Editors:**

**Surgical Pathology & Cytology**

Ahmareen Khalid

Bushra Kiyani

Hijab Shah

Athar Dil

Hafeez Imad

Ambreen Moatasim

Humaira Nasir

**Microbiology**

Mumtaz Ahmad khan

Naeem Khattak

Malik Latif Awan

Muhammad Saeed Anwar

**Hematology**

Mumtaz Ahmad Khan Momina Ali

Muhammad Saeed Anwar

Lubna Naseem

Nadia Altaf

Tariq Ehtisham

**Paediatrics Pathology:**

Dr. Naheem Ahmad

**Dermatopathology:**

Riffat Yasmen

Najia Umer

Erfan Khattak

**CNS Pathology**

Dr. Tariq Khan Hashim

Dr. Farooq Azam

**Pharmaceutics & Therapeutics**

Dr. Waheed Iqbal

Dr. Imran

**Pulmonary Pathology:**

Dr. Arsalan

**Eye Pathology:**

Dr. Maria

**Genetics**

Dr. Sami Siraj

**Endocrine Pathology:**

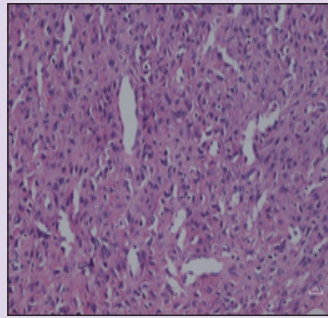
Dr. Arshad Hussain

**Chemical Pathology:**

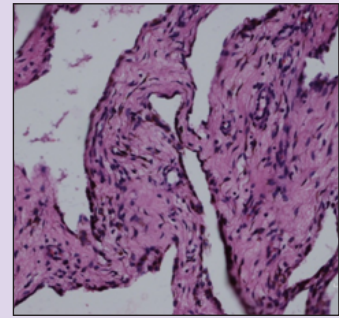
Asma Naseer Cheema

Ejaz Hassan Khan

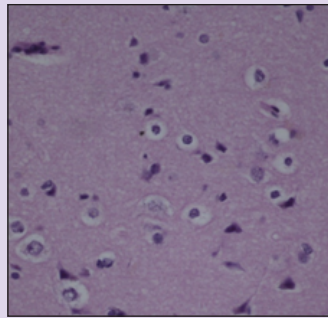
Amir Ejaz



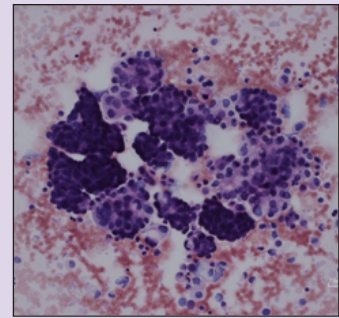
15 year old male with nasopharyngeal angiofibroma In posterolateral wall of nasal cavity (H&E 100x; scale bar: 10µm)



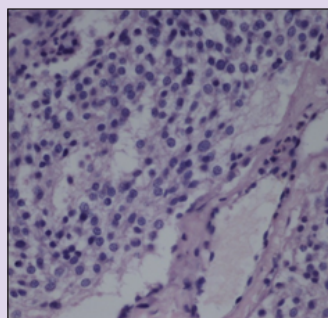
8-year-old girl with synovial hemangioma (H&E X200; scale Bar: 10 µm)



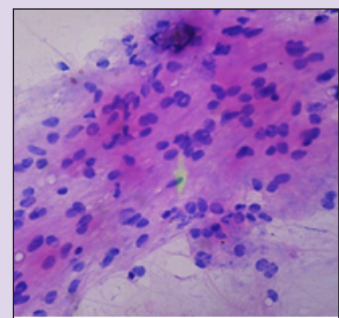
Chondroma: Benign hyper cellular hyaline cartilage (H&E X200; scale bar: 10µm)



Metastatic breast carcinoma in pleural fluid cytology (H&E X100; scale bar:10 µm)



Round, punched out nuclei with amphophilic to eosinophilic stroma surrounding branching, capillary sized vessels in glomus tumor (H&E X100;scale bar:10µm)



Touch preparation cytology Grade 2 astrocytoma (H&E X100)

**For Correspondence**

Chief Editor IJP

H. No. 116, St. 49, F-11/3

Islamabad, Pakistan - 44000

Ph: 92 51 - 2293707, 03335129849

editijp@gmail.com

Web sites: 1) <http://www.jpathology.com>

2) <http://www.pakmedinet.com>

3) <http://www.emro.who.int/emrjorlist/details.aspx?docn=1357>



Printer

Sohail Altaf Printers

Tel: 051-5770388

sohailaltaf1958@gmail.com

## Editorial Board

### General Surgery

Muhammad Iqbal Khan

### ENT:

Dr. Farooq Dr. Imran

### GI Tract Pathology:

Dr. Hanif

### Gynae Pathology:

Dr. Sidra Jabbar Khan Dr. Mehr Un Nisa

Dr. Fazilat Jamala Dr. Nuzhat Nazir Zia

### Medicine:

Dr. Abdul Khalid Awan

Dr. Munazza Adnan Dr. Iqbal

Dr. Iftikhar Shah

### Urology:

Dr. Aziz Ur Rehman Dr. Liaqat Ali

### Medical Education:

Dr. Nazish Waheed Dr. Almas Khattak

### Community Medicine:

Uzma Hafeez Adil Zarif

### Editorial Assistant:

Imran Nazir Abbasi Rahmat Khan

### Bone and Soft Tissue Pathology:

Dr. Raja Irfan Qadir



Printer

Sohail Altaf Printers

Tel: 051-5770388

sohailaltaf1958@gmail.com