

# Evaluation of Serosal Nerves in Hirschsprung Disease

Mudassira and Anwar ul Haque

Department of Pathology, Pakistan Institute of Medical Sciences, Islamabad.

**Introduction:** For the diagnosis of Hirschsprung disease (HD) and related disorders the surgical pathologists evaluate the presence or absence of ganglion cells, the morphology of ganglion cells when present and the hypertrophy and hyperplasia of nerves in Auerbach's and Meissner's plexus. The current economic health management issues make the attainment of a rapid reliable diagnosis of Hirschsprung disease highly desirable. An additional criterion apparent on hematoxylin & eosin stained sections would be of great diagnostic utility. The presence of submucosal hypertrophic or prominent nerve trunks is consistently recognized as a diagnostic clue. But the diagnostic value of serosal nerves has not been studied.

**Objective:** To establish the diagnostic usefulness of serosal hypertrophic nerves in Hirschsprung's disease on hematoxylin-eosin-stained sections.

**Study design:** It is a comparative study

**Settings:** The study was carried out in the section of Histopathology, PIMS Islamabad.

Duration of study: Jan 2004 to July 2005

**Materials & Methods:** We retrospectively evaluated the thickness of serosal nerves and compared them with the submucosal nerves in 30 diagnosed cases of Hirschsprung disease. Unremarkable resection margins from colectomy specimens were also evaluated as a control group.

**Results:** In 96.7% of cases there was significant thickening of serosal nerves. Serosal nerves were found to be more thickened than sub mucosal nerves in 40% of cases and were equally prominent in 56.7% of cases.

**Conclusion:** We found thickened serosal nerves in rectal biopsy of infants and young children with Hirschsprung disease or Syndrome. This can serve as a useful marker for diagnosis in addition to absent ganglion cells and thickened nerves in Auerbach's and Meissner's plexus.

**Key words:** Serosal nerves, Hirschsprung disease, Hirschsprung syndrome, aganglionic segment.

## Introduction

For the diagnosis of Hirschsprung disease (HD) and related disorders the surgical pathologists evaluate the presence or absence of ganglion cells, the morphology of ganglion cells when present and the hypertrophy and hyperplasia of nerves. With advancement of our understanding and classification of Hirschsprung disease and other gastrointestinal innervation disorders, a thorough assessment of morphological features by a pathologist is important to better define the spectrum of HD and other dysganglionoses. The current economic health management issues make the attainment of a rapid reliable diagnosis of abnormal innervation highly desirable.<sup>1</sup> The absence of ganglion cells is the standard for diagnosis of HD. An additional criterion apparent on hematoxylin & eosin stained sections would be of great diagnostic utility. The presence of submucosal hypertrophic or prominent nerve trunks is consistently recognized as a diagnostic clue.<sup>2,3</sup> But

the diagnostic value of serosal nerves has not been studied. This study is aimed at evaluation of the morphology of serosal and sub mucosal nerves. The aim of this study was to study the morphology of serosal nerves in cases of Hirschsprung disease and to compare them with submucosal nerves.

## Materials and Methods

This study was conducted in pathology department PIMS. Records of cases of HD diagnosed during the period of Jan 2004 to July 2005 were retrieved. This included computer records of the reports and the H&E stained slides of all cases of HD diagnosed on open seroromuscular rectal biopsies. The cases included HD patients of both sexes and age less than 10 years. Cases in which no serosal layer was present in the section were excluded from study

**Study design:** A comparative study

To assess the nerve thickness an in built criteria was selected i.e. the slides were reviewed and the serosal nerves were compared with the submucosal nerves for thickness and graded from 1 to 3 as follows:

1. Submucosal nerves thicker than serosal nerves.
2. Submucosal nerves equal in thickness to serosal nerves.
3. Serosal nerves thicker than submucosal nerves.

Surgical resection margins from colectomy specimens were taken as control group to see the normal relation of nerves in the colon. They were also graded as above.

### Results

A total of 50 cases of HD were retrieved from the records from Jan 2004-July 2005. Out of this serosa was not appreciated in 20 cases which were then excluded. Our study group comprised of 30 cases. The age range was between 2 to 10 years with median of 2 years and mean of 2.4 years. 23 were male patients and 7 were female. In 20 cases ganglion cells were totally absent; in 4 cases one or two ganglion cells were present while in 6 cases dysplastic ganglion cells were present which were compatible with neuronal dysplasia or Hirschsprung syndrome. All these cases were associated with submucosal nerve hyperplasia. The thickness of serosal nerves was compared with that of submucosal nerves in 30 cases and 10 control cases.

**Table 1: NERVE THICKNESS IN CONTROL GROUP**

	NO OF CASES	%AGE
SUBMUCOSAL>Serosal NERVES	6	60
SUBMUCOSAL=Serosal NERVES	2	20
SUBMUCOSAL<Serosal NERVES	2	20
TOTAL	10	

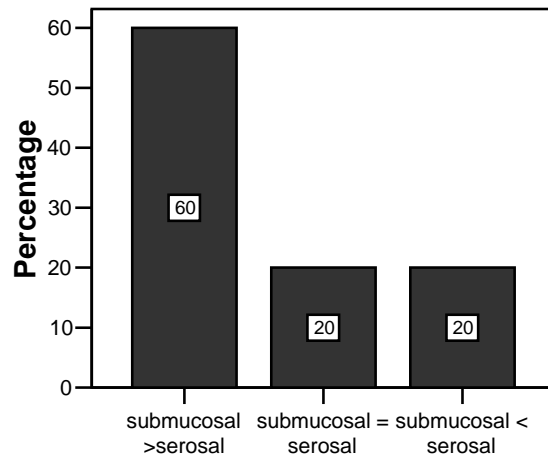
The study revealed 17 cases (56.7%) in which serosal and submucosal nerves were of equal thickness. In 12 cases (40%) the serosal nerves were thicker than the submucosal nerves. In only one case (3.3%) submucosal nerves were thicker than serosal nerves. (Table 1&2)

In control group of the surgical resection margins from colectomy specimens both the Auerbach's and Missener's nerve plexus and the serosal nerves were inconspicuous and few in number. There were 6

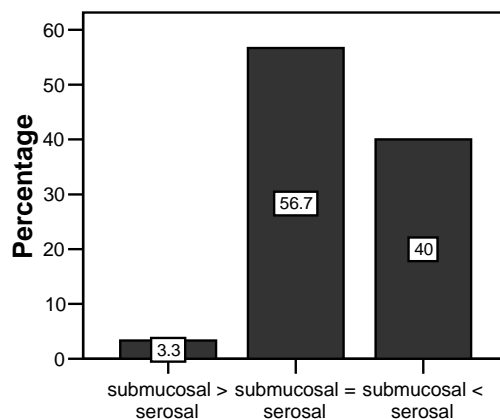
cases (60%) in which a few nerves in submucosa were greater in thickness than the serosal nerves.

**Table 2: NERVE THICKNESS IN HIRSCHSPRUNG CASES**

	NO OF CASES	%AGE
SUBMUCOSAL>Serosal NERVES	1	3.3
SUBMUCOSAL=Serosal NERVES	17	56.7
SUBMUCOSAL<Serosal NERVES	12	40
TOTAL	30	100



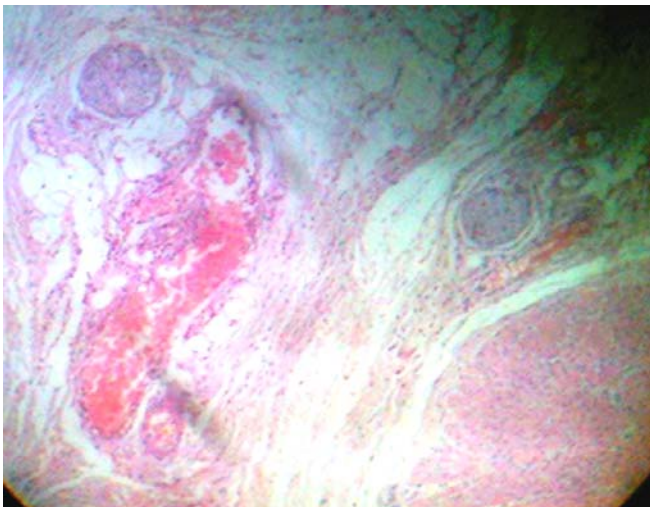
**Fig. 1 COMPARISON OF NERVE THICKNESS IN CONTROL GROUP**



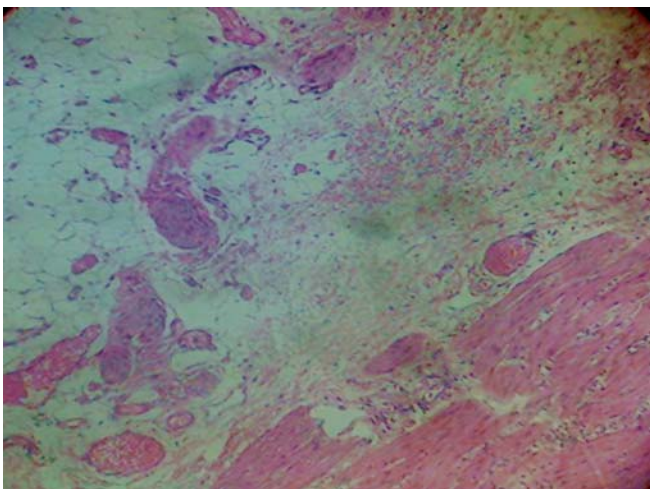
**Fig. 2 COMPARISON OF NERVE THICKNESS  
IN HIRSCHSPRUNG CASES**

## DISCUSSION

Hirschsprung disease is a congenital disorder characterized by the absence of ganglion cells in the large bowel, leading to functional obstruction and colonic dilatation proximal to the affected segment. It affects boys 4-6 times more than girls.<sup>4</sup> It has been suggested that the disease results from failure of neuronal crest cells to colonize the gut wall.<sup>5</sup> In some cases although ganglion cells are present but these are non functional and the patient presents with the features of Hirshprung's disease. These cases not only share the clinical features with the classic disorder but also the hyperplasia and hypertrophy of the submucosal nerve fibers.



**Fig. 3: Photomicrograph showing Thick Serosal Nerves (H&E 200X)**



**Fig. 4: Photomicrograph showing Thick Serosal Nerves (H&E 200X)**

### Serosal Nerves (H&E 200X)

The diagnosis of HD is usually based on a combination of the presenting symptoms, the radiological appearance of the bowel, rectal manometry, and histological features of rectal biopsies. Typical histological features of HD include the absence of ganglion cells and increased numbers of hypertrophic nerves<sup>6-9</sup>

In our study the serosal nerves were more prominent than the sub mucosal nerves in 40% of the cases while in 56% of the cases both were of equal thickness. (Fig 1&2) The diagnosis of HD or Hirschsprung Syndrome (neuronal dysplasia) is based on absence of ganglion cells in Meissner's submucosal and Auerbach's intermuscular plexuses in the former and dysplastic neurons in the latter. The loss of normal ganglion cells is usually associated with the hyperplasia and hypertrophy of the nerves in the two plexuses. Acetylcholinesterase stains demonstrate the increased network of coarse, thickened, and irregular cholinergic nerve fibers within these plexuses in affected segments of HD.<sup>10</sup> This study shows that along with the previously mentioned nerves, the serosal nerves also undergo hypertrophy and hyperplasia. ( Fig.3 &4) This morphological finding can serve as an additional diagnostic criterion. Also the thickened nerves in the rectal biopsy can be of paramount importance when ganglion cells although present, are nonfunctional.

The absence of ganglion cells in a rectal biopsy is the main stay of diagnosis for HD<sup>4</sup>. Additional features can also be found like muscle hypertrophy and vacuolation of nerves. To evaluate the absence of ganglion cells several serial sections are required which is not cost and time effective. It needs great vigilance to completely exclude the presence of ganglion cells. The search for a positive parameter has led to the use of enzyme histochemistry for acetylcholinesterase as evidence of abnormal innervation.<sup>8, 10</sup> Various immunohistochemical markers are used to highlight otherwise inconspicuous ganglion cells, and also to confirm or exclude whether the cell in question is in fact a ganglion cell. The acetylcholinesterase stain requires a separate frozen tissue biopsy specimen; the procedure is difficult technically, requiring experience in its performance. For those institutes where use of immunohistochemistry is a routine, it is the most valuable method for the evaluation of HD. However in situations where such sophisticated methods are not routinely used, an additional parameter on H&E stained sections is invaluable.

Since nerves are readily apparent on H&E stained specimens and finding of hypertrophic nerves being a positive finding rather than exclusion; this parameter is easier to evaluate. Therefore if the cells do not show convincing morphological characteristics of ganglion cells on H&E, thickness of nerves including serosal should be considered as one of the alternatives. Also in cases of neuronal dysplasia where ganglion cells are present but appear morphologically abnormal and dysplastic, the thickening of nerves can be of paramount importance in reaching a definite diagnosis.

## References

- 1- Teitelbaum DH. Hirschsprung's disease in children. *Curr Opin Pediatr.* 1995;7:316-322.
2. Kluk P, Van der Kamp A, et al. Hirschsprung's disease studies with monoclonal antineurofilament antibodies on tissues sections. *Lancet.* 1984;1:652-653
3. Robey SS, Kuhajada FP, Yardley JH. Immunoperoxidase stains of ganglion cells and abnormal mucosal nerve proliferations in Hirschsprung's disease. *Hum Pathol.* 1988;19:432-437.
4. Isabella E, Jones MJB. Diagnosis and molecular pathology of hirschsprung's disease. In: Lowe DJ; Underwood JCE editors. *Recent Advances in Histopathology* 19<sup>th</sup> ed, Edinburgh: Churchill Livingstone 2001;51-66
5. Kapur RP. Contemporary approaches toward understanding the pathogenesis of Hirschsprung disease. *Pediatr Pathol.* 1993 Jan-Feb;13(1):83-100. Related Articles, Links
6. Bodian M, Stephens FD, Ward BCH. Hirschsprung's disease and idiopathic megacolon. *Lancet* 1949;1:6-11.
7. Larsson LT. Hirschsprung's disease—immunohistochemical findings. *Histol Histopathol* 1994;9:615-29.
8. Qualman SJ, Murray R. Aganglionosis and related disorders. *Hum Pathol* 1994;25:1141-9.
9. Yunis EJ, Dobbins EW, Sherman FE. Rectal suction biopsy in the diagnosis of Hirschsprung's disease in infants. *Arch Pathol Lab Med* 1976;100:329.
10. Huntley CC, Shaffner LD, Challa VR, Lyerly AD. Histochemical diagnosis of Hirschsprung disease. *Pediatrics.* 1982 Jun;69(6):755-61.