

# Ventilating Anterior Nasal Packing after Septoplasty

Muhammad Farooq

Department of ENT, Azad Jammu and Kashmir Medical College, Muzaffarabad

**Abstract:** Anterior nasal packing after septoplasty is commonly employed by most of otorhinolaryngologists for haemostasis and splintage action. However it has complications which are usually manageable but rarely can become fatal particularly in high risk patients.

**Objectives:** Present study was aimed to find out significance of ventilating nasal packing after septoplasty to minimize complications of nasal packing.

**Patients and Methods:** This prospective and comparative study was conducted in one hundred patients to find out the benefits of ventilating anterior nasal packing after septoplasty, as compared to conventional nasal packing for 24 hours. These patients were divided randomly by odds and even serial numbers into two equal groups. Group-A included 50 patients who received ventilating nasal packing while Group-B consisted of 50 patients who received conventional nasal packing after septoplasty. The symptoms and complications of nasal packing were recorded and compared in both groups.

**Results:** Ventilating anterior nasal packing after septoplasty in Group-A showed significantly less discomfort and complications as compared to conventional nasal packaging in Group-B patients.

**Conclusion:** Ventilating anterior nasal packing served all functions of packing like hemostasis and splintage action as well as prevented most of its complications particularly related to nasal obstruction.

**Keywords:** Ventilating anterior nasal packing, conventional nasal packing, septoplasty, postoperative complications/discomfort, Breathing straws, Endoscopic septoplasty, limited septoplasty.

HISTORY	
Date Received:	April 22, 2016
Date Sent for Reviewer:	May 11, 2016
Date Received Reviewers' Comments:	May 29, 2016
Date Received Revised manuscript:	May 30, 2016
Date Accepted:	June 1, 2016

CONTRIBUTION OF AUTHORS	
Author	CONTRIBUTION
A	Conception/Study Designing/Planning, Experimentation/Study Conduction, Analysis/Interpretation/Discussion, Manuscript Writing, Critical Review, Facilitated for Reagents/Material/Analysis

## Introduction

Deflected nasal septum (DNS) is a common disease caused by trauma or errors of development. Its incidence is quite high; about 20% in new-borns, 27% in infants and 37% in adults. Most of these patients are asymptomatic. Symptomatic DNS causing nasal obstruction, headache, epistaxis, hyposmia, sinusitis, hypoxemia or cosmetic deformity, will require septoplasty.<sup>1,2</sup> Nasal septum has three parts; collumellar, membranous and septum proper. The septum proper mainly consists of cartilage and bones. Septal deviation may involve only the cartilage, bone or both. Types of DNS are anterior dislocation, C or S-shaped deformity, spurs or thickenings.<sup>3</sup> Mladina has also classified DNS into 7 types (figure-1).<sup>4</sup>

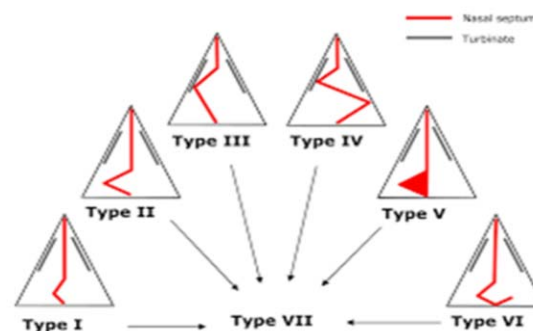


Figure 1, Mladina types of DNS

Optimum functioning of the nose mainly depends upon proper shape and position of the nasal septum. Nasal septum also supports the dorsum, collumella and tip of nose and contributes to cosmetic value of the nose.<sup>5</sup> Septoplasty, first described by Cottle in 1958 and Maran in 1974 is a tissue sparing operation where DNS is corrected by minimal resection of cartilage and

### Author's Correspondence

Dr. Muhammad Farooq, Assistant Professor ENT Azad Jammu and Kashmir Medical College Muzaffarabad. dr.farooqak@gmail.com 03350054849

bone, straightening the septum by criss-cross cartilaginous incisions and fracturing the deviated bony septum. Since introduction of the endoscopic septoplasty by Giles et al in 1994, limited septoplasty is becoming more popular.<sup>6,7</sup>

Traditional nasal packing by any material such as medicated or Vaseline gauze, paraffin mesh, synthetic materials or glove fingers; cause compulsory nasal obstruction and can lead to mucosal damage, adhesions formation and rhino-sinusitis. Rarely it can cause fatal complications like nocturnal hypoxaemia, obstructive sleep apnoea, aspiration leading to lung collapse, toxic shock syndrome and pulmonary oedema.<sup>8-10</sup> As these patients are forced to breathe through mouth, they often has unsmooth and late recovery from general anesthesia, dryness of mouth, blockage of ears, sleep disturbance and stress. Ventilating nasal packs allows the patient to breathe through nose avoiding all complications associated with nasal obstruction. Ventilation tubes also allow to do suction of blood or secretions from the post-nasal space.<sup>11-12</sup>

Nasal packing can cause significant increase in nocturnal blood pressure in normotensive patients but it may reflect more significantly in cardio-vascular disease patients, even if their blood pressure is under control by medicines. Nocturnal sudden death can occur in these patients after nasal packing, most probably due to stroke or myocardial infarction.<sup>13</sup> Nasal packing can also cause hypoxaemia which in normal persons, is not severe enough to cause tissue hypoxia. However in patients with impaired pulmonary functions, nasal packing can cause tissue hypoxia precipitating life threatening lactic acidosis along with increase in PCO<sub>2</sub> and HCO<sub>3</sub> levels. Therefore patients with cardio-pulmonary disease can be benefited with ventilating nasal packs with closed monitoring in intensive care unit (ICU).<sup>14</sup>

Endoscopic septoplasty can be performed followed by functional endoscopic sinus surgery (FESS) if indicated, allowing additional time to assess the septal pocket for any hematoma formation. A small (5mm) stab incision can be made in posterior third of contralateral or ipsilateral mucosal flap to prevent hematoma formation.<sup>15</sup> An ideal nasal pack should have good hemostatic and splinter actions with less discomfort and minimal complications.<sup>16</sup> Although nasal packing material with airway is commercially available but it is costly, not freely available, has small airway lumen, difficult to insert because of large width and does not apply the desired pressure over the nasal septum (figure-2).<sup>17</sup> In this study, more suitable

airways prepared from non-cuff endotracheal or nasogastric tube were used.

## **Methodology**

This was a prospective and comparative experimental study, conducted in United Hospital Rawalakot AJK for a period of 18 months, from September 2013 to February 2015. Objective was to find out significance of ventilating anterior nasal packing after septoplasty. It was a single blind type of study as the patients did not know the type of treatment they received. One hundred patients who received bilateral nasal packing after septoplasty were included in this study. In all patients, a detailed relevant history was obtained and a general physical and otorhinolaryngical examination was carried out. Relevant investigations such as complete blood picture, bleeding and clotting time prothrombine and activated partial thromboplastine time, blood grouping, viral hepatitis tests, urine examination and x-ray paranasal sinuses were done. Information and findings about each patient were recorded on a predesigned Performa. Approval from hospital's ethical committee was taken prior to start of the study. All patients were operated by the author.

Inclusion criteria: Patients having DNS with symptoms (nasal obstruction, epistaxis, headache etc.) or complications like rhino-sinusitis, otitis media, pharyngitis etc. were included in this study.

Exclusion criteria: Patients requiring revision Septoplasty or with underlying chronic systemic illness like hypertension, diabetes mellitus, anemia, viral hepatitis etc. were excluded from the study.

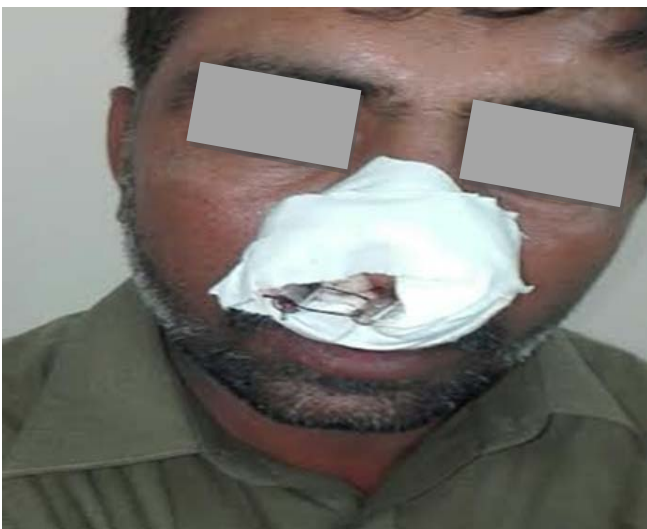Patients were randomized into two equal groups by alternate allocation by odds and even serial numbers. Both Groups-A and B consisted of 50 patients each. Informed consent was taken from all patients after explaining all the risks and benefits of the operation. Special consent was taken from patients whose pictures were used in this article. Septoplasty was performed in all patients under local anesthesia (LA) or general anesthesia (GA) as deemed necessary. About 10-20 ml of 2 percent lignocaine with 1 in 200,000 adrenaline was infiltrated into nasal septum to reduce bleeding during operation. In Group-A patients after septoplasty, medicated gauze bilateral ventilating nasal packing was applied. The ventilating tubes were prepared from number 4-5 poly-vinyl chloride (PVC) non cuff endotracheal tube (figure-3, 4) or FR 16-20 size nasogastric tube (figure-5, 6). In Group-B patients, conventional medicated bilateral nasal packing was applied without ventilating tubes.




**Fig.2: Commercially available Silicone nasal septal splints with airway**



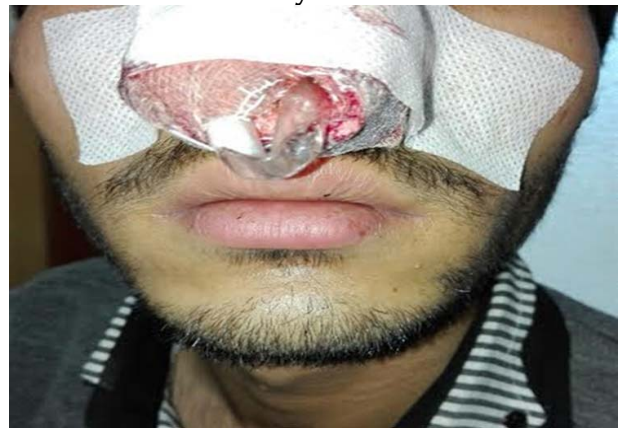**Figure-3: Number-5 non cuff endotracheal tube and two tubes carved from it**



**Figure-4: Nasal packing with ventilating tubes carved from number-5 endotracheal tube**



**Figure-5: FR-16-20 nasogastric tube and 2 types of nasal airways carved from it**



**Figure-6: Nasal packing with airways carved from nasogastric tube**

All patients were admitted for up to 24 hours. Postoperatively all patients received analgesic, anti-histamine, decongestant nasal spray and antibiotic for 5-7 days. In patients with ventilating nasal packing, frequent suction was applied or saline irrigation was done to keep the tubes patent. Nasal packing was removed after 24 hours. Patients were followed up for 12 weeks. All patients were assessed for complications of septoplasty such as difficult recovery from GA, nasal obstruction, dryness of mouth, nasal bleeding, nasal pain or headache, sleep disturbance, difficulty in swallowing and speaking, epiphora, fever, ear blockage, septal hematoma, adhesions etc. Statistical analyses of the obtained results were performed using SPSS version-23. Means and standard deviations were calculated. On WWW.GraphPad.com, the two tailed p-values were calculated by using unpaired t-test. P-value equal or less than 0.05 was considered significant.

## Results

There were 66 males and 34 females in this study and ages varied from 16 to 58 years. The mean age was 34 years. Differences in symptoms and complications of nasal packing in both groups were depicted in table-1.

**Table-1: Symptoms and complications of nasal packing**

Symptoms/Complications	Group-A	Group-B	P-Value
Difficult recovery from general anesthesia	24%	92%	< 0.0001
Nasal obstruction	12%	100%	"
Dryness of mouth	16%	92%	"
Disturbance of sleep	24%	80%	"
Nasal pain and headache	68%	96%	"
Dysphagia	32%	44%	"
Epiphora	60%	80%	"
Nasal bleeding	28%	24%	> 0.05
Fever	20%	24%	"
Ear blockage	28%	32%	"
Septal hematoma	Nil	Nil	"
Nasal adhesions	8%	4%	"

The recovery from general anesthesia in Group-A was difficult only in 24% as compared to 92% in Group-B patients. In majority of Group-A patients' recovery from GA was smooth and rapid saving 5-10 minutes of recovery time.

## Discussion

In this study the mean age of presentation was 34 years and majority of the patients were in the age range of 16 to 45 years. The male to female ratio was about 2:1. The main complaints were nasal obstruction, rhinorrhea and sinus headache. These results were almost similar to a study by Kurtaran H et al in 2009 and another study in 2014, by Rakesh Saboo and Amit modwal.<sup>1,18</sup> After septoplasty most of Otorhinolaryngologists perform nasal packing for hemostasis and splintage action. However this bilateral nasal packing is not innocent and can cause significant discomfort and complications.

In this study majority of the bad effects of bilateral nasal packing were prevented by using ventilating nasal packs. The problems of difficult recovery from general anesthesia, nasal obstruction, dryness of mouth and sleep disturbances were found

significantly less (24%,12%, 16% and 24%)in Group-A as compared to Group-B patients(92%, 100%, 92% and 80%). Nasal pain/ Headache, dysphagia, and epiphora were less commonly seen (68%, 32% and 60%) in Group-A as compared to Group-B patients (96%, 44% and 80%). All above results are statistically highly significant and has p-value of less than 0.0001. However other complications of bilateral nasal packing like blockage of ears, fever and adhesions formations were found almost equal in both groups of patients and has p-value of above 0.05. These results are comparable with results of various other studies.<sup>1,11,16,19</sup> Septal hematoma was not seen in any patient and this may be due to better operation technique, formation of a small (5-10mm) hole in posterior third of muco-perichondrial flap on either side and trans-septal suturing.<sup>15,20</sup>

As nocturnal oxygen desaturation occurs in patients with bilateral nasal packing after nasal surgery or epistaxis, this factor must be taken into account particularly in patients with chronic obstructive pulmonary disease(COPD), ischemic heart disease(IHD), obesity and sleep apnoea syndrome(SAS).<sup>14,17,21</sup> In these patients the best option will be ventilating anterior nasal packing.

The only complication of ventilating nasal tubes mentioned in the literature was blockage of tubes due to crusts and clots. Nasal irrigation with normal saline or regular suction of tubes can prevent blockage of ventilating tubes.<sup>18</sup> However, I faced some other complications in few cases such as difficulty in insertion of ventilating tubes, mucosal injury, turbinate injury, tubes displacement and nasal bleeding. These complications were prevented in later cases by taking great care. Risk of accidental aspiration or ingestion of displaced tubes was prevented by adequately stitching the anterior ends of both ventilating tubes with 2/0 silk.

## Conclusion

Ventilating anterior nasal packing was more beneficial than conventional nasal packing after septoplasty as it served all functions of packing and prevented most of its complications, particularly related to nasal obstruction. It is particularly useful for patients having cardio-pulmonary disease who need nasal packing for septoplasty or epistaxis.

## References

1. Saboo R and Modwal A. Septoplasty: Postoperative Alternative for control of hemorrhage and discomfort. Sch. J. App. Med.Sci; 2014; 2(4D): 1376-1380.

2. Harugop AS, Mudhol RS, Hajare PS, Nargund AI, Metgudmath VV and Chakrabart. Prevalence of Nasal Septal Deviation in New-borns and Its Precipitating Factors. *Indian J Otolaryngol Head Neck Surg.* 2012 Sep; 64(3):248-251.
3. Dhingra PL, Dhingra S. Nasal septum and its diseases. In: Elsevier, editor. *Diseases of ear, nose and throat & Head and Neck Surgery.* 6th edition India, 2014; p.147-151.
4. Mladina R, Cuji R, Subaru M, Vukovi K. Nasal septal deformities in ear, nose and throat patients: An international study. *Am J otolaryngol.* 2008; 29:75-82.
5. Adriaan F, Von Olphen. The septum. In Michael Glesson, Editors. *Scott Brown's Otolaryngology.* 7th edition. Edward Arnold (pub), 2008; Vol-2; 1589-1595.
6. Apaydin F, Angelos PC, Toriumi DM. Functional rhinoplasty, Nasal septal reconstruction. In *Recent Advances in Otolaryngology Head and Neck Surgery*, Lalwani A.K and Pfister M.HF; Editors, 2012: 276-333.
7. Hazarika P, Nayak D.R and Balkrishan R. Diseases of the nasal septum. In CBS Publishers and Distributors. *Textbook of Ear, Nose, throat, Head & neck surgery: clinical and practical.* 3rd edition. India, 2014: 279-289.
8. Siddique M, Haq IU, Haq AU. A case report-Bilateral lung collapse due to aspirated nasal packing. *Int J of Anesth, pain & Intensive care.* 2009;13(2): 75-77
9. Naghibzadeh B, Peyvandi AA and Naghibzadeh G. Does post-septoplasty nasal packing reduce complications? *Acta Med Iran.* 2011;49(1):9-12.
10. Kristensen S, Bierregaard P, Jensen PF, Juul A. Post-operative nocturnal hypoxia in septoplasty: the value of nasal packing with airway tubes. *Clin Otolaryngol ALLIED Sci.* 1996 Aug;21(4): 331-4.
11. Khan N, Hameed M.K, Ayub Z, Alam M.J. Comparison of Improvised Ventilating nasal packs with Vaseline gauze Packs in Nasal Surgery. *JIIMC.* 2013; 8(3): 74-77.
12. Dhanasekar G, Simmen D, Briner HR. Breathing straws. *J Laryngol Otol.* 2010 Jan; 124(1): 73-4.
13. Deniz M. et al. The effects of nasal packs on systemic blood pressure after septoplasty. *KBS -Forum Afyon Turkey.* 2004; 3(4), [www.KBB-Forum.net](http://www.KBB-Forum.net).
14. Goel L, Goel H.F, Naik A. Impact of nasal packaging on arterial blood gases and acid base balance. *The pharma Innovation journal* 2016; 5(1): 106-108
15. Jonnalagadda S, Vivian Y, Catalano P. Minimally invasive Endoscopic septoplasty-A review of a novel technique and clinical outcomes. *Odisha journal of Otorhinolaryngology and HNS:* 2014; 8(II): 5-9.
16. Kim Y.H, Kim S.R, Park J.H and Han Y.S. The usefulness of nasal packing with Vaseline gauze and airway silicone splint after closed reduction of nasal bone fracture. *Arch Plast Surg.* 2012 Nov; 39(6): 612-617.
17. Gupta M, Singh S and Chauhan B. Comparative study of complete nasal packaging with and without airways. *B-ENT;* 2011: 7; 91-96
18. Kurtaran H, Ark N, Sadikoglu F et al. The effect of anterior nasal packing with airway tubes on pulmonary function following septoplasty. *Turk J Med Sci.* 2009;39(4): 537-540.
19. Karahatay S, Birkent H, Demir D, Ceyhan A, Satar B. The effects of ventilated and non-ventilated nasal packs on Eustachian tube function: nine-step inflation deflation test results. *Rhinology.* 2006 Sep; 44(3): 197-200.
20. Ansari MA, Islam U, Hirani I, Khayani IAM, Ziauddin A. Trans-septal suturing technique without intra-nasal packing. *Pak J Sug.* 2013;29(2)132-126.
21. Armengot M, Hernandez R, Miguel P, Navarro R, Basterra J. Effects of total nasal obstruction on nocturnal oxygen saturation. *Am J Rhinol.* 2008 May-Jun; 22(3): 325-8.