

Significance of Invitro Isolation of *Alternaria alternata* from Onychomycotic Patients

Umme Farwa, Wajiha Farooq, Asim Saeed and Shagufta Hussain

Department of Pathology, Yusra Medical and Dental College, Islamabad

Abstract

Objectives: To determine the isolation rate of *Alternaria alternata* in patients with clinical Onychomycosis

Study Design: Descriptive (cross sectional) study

Place and Period of Study: Department of Microbiology, Armed Forces Institute of Pathology Rawalpindi, from August 2011-April 2012.

Material and Methods: Sample size; 200 nail samples, Sampling Technique; Non probability convenience sampling. Nail clippings and nail scrapings were obtained from affected nails of patients clinically having onychomycosis. Direct microscopic examination with 30% potassium hydroxide mounts and culture on Sabouraud's dextrose agar (SDA), SDA containing Chloramphenicol, and SDA containing actidione and chloramphenicol were used for species identification.

Results: Out of 200 nail specimens, 94 (47%) yielded positive fungal growth, while 106 (53%) nail specimens were found negative on culture.

Non-dermatophyte moulds (NDMs) accounted for 62 (66%) of total culture positive cases, out of which *Alternaria alternata* was the commonest species (29%).

Dermatophytes were isolated from 20 (21%) all belonging to genus *Trichophyton* spp. and 12 (13%) were yeast.

Conclusion: Study has yielded high number of NDMs especially *Alternaria alternata*, hence large scale multicentre clinical studies are required to ascertain the clinical significance of *Alternaria alternata* as pathogen particularly in patients with immunosuppression, as a causative agent of onychomycosis. Moreover, clinical trials to see the treatment outcome of NDMs isolated from these patients, will further help to unfold the clinical significance of this study.

Key words: *Alternaria alternata*, non-dermatophytes, dermatophytes, onychomycosis and yeast.

Introduction

Fungal infections have become a significant health problem affecting all age groups. Correct diagnosis is important not only for initiating appropriate and timely treatment but also for epidemiological record. The recognition of the pathogen helps the treatment approach and potential implementation of control measures. The prevalence of dermatophytes, non-dermatophytes and yeasts tends to vary with different time of the year as well as on the basis of geographic location.^{1, 2}

Onychomycosis is a term derived from Greek word "onyx", means a nail and "mykes", means a fungus. It is a fungal infection of nails and is amongst the most

common causes of distorted nails, and accounts for almost 50% of all nail diseases.³ It represents about 30% of all mycotic cutaneous infections.⁴ Increasingly onychomycosis is being viewed as more than a mere ornamental problem. In spite of better personal sanitation and living environment, onychomycosis continues to spread. The prevalence rate of onychomycosis is determined by age, predisposing factors, social condition, profession, climate and living environment.⁵

Although Dermatophytic Moulds/ Non Dermatophyte Moulds were previously regarded as contaminants, yet they are now progressively recognized as pathogens in nail infections. They are being held responsible for 1.5-6% of all cases of onychomycosis.⁶ Certain classes of patients show raised incidence of onychomycosis due to NDMs. Such patients include elderly, immunocompromised, particularly those with granulocytopenia below 1,000 cells/ml, patients with invasive procedure, AIDS and keratin abnormalities.^{7, 8, 9} Onychomycosis in immune compromised patients can pose not only a serious health problem but patient may also suffer social embarrassment.

Contribution of Authors: Please see after references

Correspondence: Dr. Umme Farwa, Assistant Professor Microbiology, Department of Pathology, Yusra Medical and Dental College, Islamabad, Pakistan
Email: farwaimran@hotmail.com

Article Received: 12.11.2014

Accepted: 20.08.15

It is not known whether non dermatophyte infections occur as a primary ailment on healthy nails or exist as secondary invaders in already damaged nails by ischemia, trauma or other diseases. Non dermatophyte which are regularly isolated in onychomycosis include *Alternaria* spp, *Fusarium* spp, *Scytalidium* spp, *Acremonium* spp, *Scopulariopsis* spp, *Cladosporium* spp and *Aspergillus* spp.¹

Until 1990s onychomycosis was a poorly discussed topic. Even in developed countries, the importance of nail infections has been highlighted only in the last decade.¹⁰ In the third world countries like Pakistan, socioeconomic tribulations and other common prevalent health issues have affected the awareness level of Onychomycosis among physicians and general population. There are many studies on dermatophytes but there are few on NDMs from infected nails. Therefore, to address this topic in Pakistan and to carry out further research a study was done in 2009 with a aim to determine the major pathogens involved in clinical onychomycosis, in which it was observed that NDMs were more than dermatophytes.¹¹ Based on these findings a more detailed study was hence planned on bigger sample size and more strict sample collection protocol so as to eliminate all the elements contributing to contamination and small sample size.

Methodology

The study was carried out at Microbiology Department, Armed Forces Institute of Pathology, Rawalpindi from August 2011-April 2012. It was a cross sectional study, with non-probability convenience sampling. No discrimination was made on the basis of age or gender.

A total of 200 patients were included applying the following inclusion criterion : Nails with different abnormalities like subungual hyperkeratosis, nail thickening, brittle nails, pitting of nails and change in colour of nail plate such as blackening, white or yellow discoloration. Patients ending up with anti fungal treatment failure after taking therapy for at least two months for dermatophytes, having stopped this treatment two weeks prior to submission of sample and all direct microscopic samples whether negative or positive were also included.

Patients on anti fungal drugs, those suffering from other skin diseases like psoriasis and lichen planus and repeat samples of the patient were excluded from the study.

After taking a thorough history and demographic details on specifically designed performa, nail was scrubbed with 70% ethyl alcohol. Subungual

keratinous debris were collected along with nail clippings.

Part of the nail sample was immersed in a drop of 30% KOH over a slide and kept in humidified boxes over night for direct microscopic examination next day. The next half of nail sample was simultaneously inoculated on three different points on each plate using three types of media, Sabouraud's dextrose agar (SDA) (Oxoid, UK), SDA containing chloramphenicol (0.05gm/l) (without actidione), SDA containing chloramphenicol (0.05gm/l) with actidione(100mg/l). The inoculated specimen were incubated in cool incubator (22°C) for up to three weeks after placing them in polythene zipper bags to prevent contamination.^{2, 12} The culture plates were examined two times per week for any growth. Colonial morphology of any appearing growth was noted. Species identification was done through colony morphology and its microscopic examination using lactophenol blue wet preparation.

All collected data obtained was entered and analyzed by using SPSS 18. Mean SD \pm for age was calculated, frequencies and percentages were calculated for gender, direct microscopic examination and pattern of species. Descriptive statistics was applied to the data. All ethical considerations and obligations were properly addressed and the study was conducted after approval by ethical committee.

Results

A total of 200 nail specimens were included in the study. Out of total specimens, 118 were from females and 82 were from males. Female to male ratio turned out to be 1.4:1. Age of the patients ranged from 04-70 years. The most affected age group in our study was 31-40 years with mean of 36.0 ± 14.9

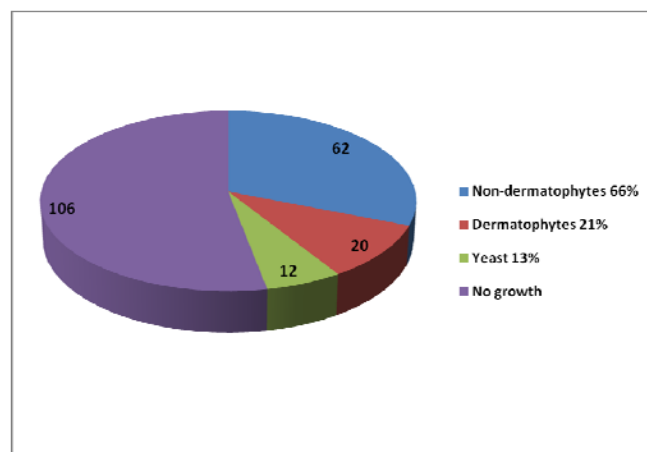


Figure I.- Percentage Distribution of different Categories of Fungal Pathogens (n=94)

Table-I: Pattern and frequency of isolation of Non Dermatophytes Molds (n=62)

SPECIES	Number	Percentage
<i>Alternaria alternata</i>	18	29
<i>Fusarium dimerum</i>	09	14.5
<i>Fusarium solani</i>	07	11.2
<i>Aspergillus species</i>	10	16.1
<i>Cladosporium sphaerospermum</i>	07	11.2
<i>Scytalidium dimidiatum</i>	07	11.2
<i>Scopulariopsis brevicaulis</i>	01	1.7
<i>Cladophialophora carrionii</i>	01	1.7
<i>Ulocladium chartarum</i>	01	1.7
<i>Pseudallescheria boydii</i>	01	1.7
Total	62	100

Amongst the 62 NDMs, *Alternaria alternata* was the major isolate found (29%) (Table: 1). Out of the total 18 specimens positive for *Alternaria alternata* half of them were KOH positive.

The other isolates were *Fusarium spp* (*F.dimerum*) (*F.solani*), *Aspergillus spp*, *Cladosporium sphaerospermum*, *Scytalidium dimidiatum*. There were also isolates of *Scopulariopsis brevicaulis*, *Cladophialophora carrionii*, *Ulocladium chartarum* and *Pseudallescheria boydii* (Table: 1) (Fig: II)

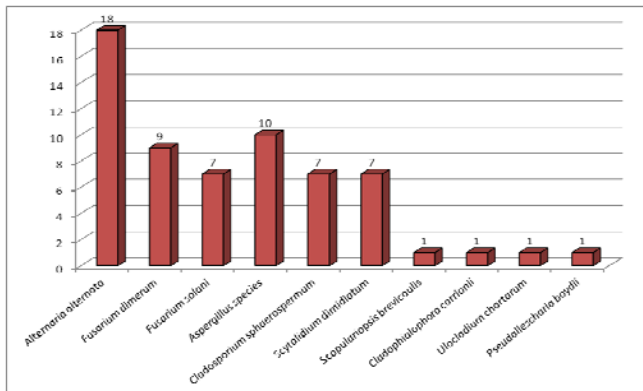


Figure II: Species of Non-dermatophyte moulds yielded in this study. (n=62)

Among dermatophytes *Trichophyton interdigitale* was the most common isolate followed by *Trichophyton*

rubrum, *Trichophyton mentagrophytes* and *Trichophyton tonsurans*. Among Yeasts, *Candida glabrata* was the most common followed by *Candida albicans* and *Candida krusei*.

Regarding the immune status of the patients 30% of total NDM and 40 % of the patients with positive culture of *Alternaria alternata* were diabetic. The rest of them had other co morbid condition like Ischemic heart disease, hypertension, prolong use of anti fungal, anti microbial and previous hospitalization. Since the majority (118) of patients were female of child bearing age an element of nutritional deficiency as a strong possibility is there.

Discussion

Alterations of immune system play a role in pathogenesis of NDMs fungal infection. Nonspecific as well as specific cellular and humoral immune mechanisms effects host resistance to fungal invasion. Functional defects in adherence, chemotaxis, degranulation and phagocytosis due to netropenia as well as granulopenia induced by immunosuppression with chemotherapy, corticosteroid, intravenous drug abuse favours the development of opportunistic onychomycosis.^{13, 14} In developing countries lack of nutrition also serves as an important risk. Other risk factors include receipt of antimicrobial agents, neutropenia prior to hemodialysis, or previous fungal colonization. Most of these factors are very common in hospitalized patients, especially in high-risk areas such as ICUs/CCU or oncology wards.

One of the finding of our study was that 66% of abnormal nails in patients, were found culture positive for NDMs, majority of them were previously treated for dermatophytes also. *Alternaria alternata* was the major pathogen, it is difficult to establish the role of *Alternaria alternata* in these specimens as primary pathogens of the nails.

To increase the predictive power of diagnosis of dermatophytes in nails, Summerbell¹⁵ suggested that NDMs identified in affected nails may be considered as one of the following.

1. Contaminant
2. Normal commensal
3. Transient saprobic coloniser
4. Persistent secondary coloniser (coloniser of material infected by a dermatophyte but incapable of remaining after the dermatophyte is eliminated)
5. Successional invader (species that can cause infection after gaining entry into a nail via the disruption caused by a primary pathogen)

6. Primary invader (able to infect and cause onychomycosis in a previously uncolonised nail)

The role of NDMs remains contentious and many studies are being carried out to define it. They have been regarded as secondary pathogens of nails which are already diseased but they may act as primary pathogens in small no of cases.¹⁶ Williams has stated that NDMs could account for 1.5% to 6% of all onychomycosis¹⁷, but their interaction with dermatophytes, preexisting ailment and nail damage is still debatable.

Although Onychomycosis due to *Alternaria alternata* is not frequent but there are several reports suggesting its involvement in onychomycosis.^{18, 19, 20, 21, 22} Contrary to the general belief of *Alternaria alternata* as a contaminant, in our study a large percentage of *Alternaria alternata* was isolated.

The specie is a saprophyte which is not only found in outdoors but also in indoors such as carpets, textile item and on horizontal surfaces of buildings. *Alternaria* produce large spores which can easily be deposited in nose, mouth and upper respiratory tract. It can cause hypersensitivity pneumonitis, sinusitis, dermatomycosis, onychomycosis, subcutaneous phaeoerythromycosis and invasive infection. . This species is capable of producing tenuazonic acid and other toxic metabolites which is associated in causing disease in humans.¹⁴

Quiet a significant number of our patients were immunocompromised due to diabetes, previous antifungal and antimicrobial therapy, nutritional deficiencies and other co morbid conditions. Onychomycosis due to *Alternaria alternata* in our study can be considered significant because samples were taken after strict aseptic technique which rules out the possibility of being contaminant. Moreover, point specific growth on multiple media used. Many of these fungi are highly sensitive to cycloheximide (actidione) and may be missed if the specimen is not also inoculated on a cycloheximide-free medium such as Sabouraud dextrose agar (SDA), potato dextrose agar or Littman's Oxgall agar¹⁸ hence any worker putting this culture on actidione media only will miss NDMs. Our half of the specimens showed the presence of the fungal elements in direct microscopic examination of the nails which grew as *Alternaria alternata* which could be proportionate to its clinical significance although Weitzman and Summerbell²³ stressed that the growth of non dermatophytes on nail culture following a positive result on direct microscopy is not sufficient to diagnose a NDM infection. People have suggested an additional

confirmatory technique for growth of the same NDM in three consecutive cultures from same patient with a week interval²⁴ which, if practiced would have refined our results further. With the growing interest in pathogenic fungi and better understanding of the importance of fungal infections in differential diagnosis, we believe that the results of our study would be very valuable for the physicians and dermatologists of the region.

This mould is being increasingly isolated and reported in different studies across the globe.^{7, 11, 25, 26, 27, 28, 29} The development in diagnostic techniques specially molecular techniques have confirmed that this specie is no more uncommon these days.²⁹ Since varying patterns of immunosuppressive agents, surgical techniques, increase in transplant recipients, renal dialysis, the initiation of AIDS treatment could contribute to the intrinsic risk for such fungal infections.³⁰

The prevalence of NDMs varies considerably in different studies reported in the literature. Reports from neighboring regions have findings quite close to the present study. In a study conducted in 2006, in Egypt, on 32 patients with different abnormal nails it was found out that NDMs were isolated from 19 patients (59%) of the total culture positive cases. Most of these NDMs were recovered from specimen taken from house wives with *Aspergillus* species being the commonest followed by *Alternaria alternata* and *Penicillium* spp.²⁵ A study conducted in Iraq in 2008, revealed that *Candida* species were most frequent followed by *Trichophyton* spp, *Alternaria alternata* and *Cladosporium* spp,²⁷ while in our study *Alternaria alternata* was the commonest specie followed by *Cladosporium* spp, *Candida* and *Trichophyton*. Comparable results were seen in a local study conducted at Rawalpindi in 2007 which showed that amongst NDMs, *Alternaria alternata* was the most common, followed by *Scytalidium dimidiatum* and *Penicillium marneffeii*.⁷

On the contrary the most common NDM isolated in studies reported from Europe³¹, North America³² and Mexico³³ were *Scopulariopsis* followed by *Aspergillus*. In our case the isolation of these two fungi was low. *Scytalidium dimidiatum* was reported in the past at same centre^{7, 34} in two different studies but in this study only one isolate of the specie was recovered from patients of onychomycosis.

Some of the studies carried out in our country show that *Candida* was the commonest pathogen followed by *Trichophyton*, *Fusarium* and *Alternaria* species.²⁶ Similarly, dermatophytes were reported as primary

isolate followed by non-dermatophytic moulds in studies from Mexico and Malaysia in patients of onychomycosis.^{35, 36} The isolation of dermatophytes in our study was quite stumpy accounting for only 15% of the total isolates. One of the possible explanations for this might be that the majority of patients in this study have been previously treated for dermatophytes and might be secondarily invaded by NDMs leading to negative results in culture. Confirmatory technique for growth of the same NDM in three consecutive cultures from same patient with one week interval if practiced would have helped to resolve the issue.

Conclusion

The outcome of our study has revealed that there are a large percentage of patients whose nails have grown Non-dermatophytes. Since NDMs are being incriminated as pathogen in onychomycosis in both immunocompetent and immunocompromised patients, especially diabetics, those using broad spectrum antibiotics/antifungals and subjected to localized trauma; hence this group of fungi should be considered significant with a high index of suspicion in patient's negative for dermatophytes on culture or those ending up in treatment failure.

The findings of this study are pointing towards a significant role of NDMs and it demands more detailed, comprehensive laboratory based and clinical studies to elaborate clearly the role of these emerging pathogens in nail infections.

References

1. Agarwalla A, Agrawal S, Khanal B. Onychomycosis in eastern Nepal: *Nepal Med College J* 2006; 8 (4): 1-7.
2. Denning DW, Kibbler CC, Barnes RA. British Society for medical mycology proposed standards for patients with invasive fungal infections. *Lancet Infect Dis* 2003; 3:230-40.
3. Faergemann J, Baran R. Epidemiology, clinical presentation and diagnosis of onychomycosis. *Br J Dermatol* 2003;149:1-4.
4. Summerbell RC. Epidemiology and ecology of onychomycosis. *Dermatology* 1997; 194 : 32-6.
5. Kaur R, Kashyap B, Bhalla P. Onychomycosis-epidemiology, diagnosis and management: *Indian J Med Microbiol* [serial online] 2008 [cited 2009 jan 12]; 26: 108-16. Available from: <http://www.ijmm.org/text.asp?2008/26/2/108/40522>
6. Greer DL. Evolving role of nondermatophytes in onychomycosis. *Int J Dermatol* 1995; 34: 521-4.
7. Hanif F, Ikram A, Butt T, Malik N, Qadir IH, Faiz U, Trends of fungal isolates in our set up. *Infect Dis Pak* 2009; 18: 3-5.
8. Garcia-Martos P, Dominguez I, Marin P, Linares M, Mira J, Calap J. Onychomycoses caused by non-dermatophytic
10. filamentous fungi in Cadiz. *Enferm Infecc Microbiol Clin* 2000; 18: 319-24.
11. Scher RK. Onychomycosis: A significant medical disorder. *J Am Acad Dermatol* 1996; 35 (part 2): S2-S5.
12. Weeks J, Elewski B. Management of superficial infections. In: Merz WG, Hay RJ, eds., *Topley and Wilson's*, 10th ed., London: Hodder Arnold; 2005. p. 182-89.
13. Farwa U, Abbasi SA, Mirza IA, Amjad A, Ikram A, Malik N, Hanif F. Non-Dermatophyte Moulds as an emerging Pathogens of Onychomycosis. *JCPSP* 2011; 21 (10): 597- 600.
14. Borman AM, Campbell CK, Fraser M, Johnson EM. *Med Mycol* 2007; 45:131- 41.
15. Murphy JW, Wu-Hsieh BA, Singer-Vermes LM. Cytokines in the host response to mycotic agents. *J Med Vet Mycol* 1994; 32 (1): 203-10.
16. Drouhet E. Historical introduction: evolution of knowledge of the fungi and mycoses from Hippocrates to the twenty-first century. In: Merz WG, Hay RJ, eds., *Topley and Wilson's Microbiology and Microbial Infections*, 10th ed., London: Hodder Arnold; 2005. p. 03-42.
17. Summerbell RC. Epidemiology and ecology of onychomycosis. *Dermatology* 1997; 194: 32-6.
18. Ellis DH, Watson AB, Marley JE, Williams TG. Non-dermatophytes in Onychomycosis of the Toe Nails. *Br J Dermatol* 1997; 136: 490-3.
19. Williams HC. The epidemiology of onychomycosis in Britain. *Br J Dermatol* 1993; 129: 101-9.
20. Campbell CK, Johnson EM. Dermatocytoc molds. In: Merz WG, Hay RJ, eds., *Topley and Wilson's, Microbiology and Microbial Infections*. 10th ed., London: Hodder Arnold; 2005. p. 244-54.
21. Singh SM, Naidu J, Pouranik M. Ungual and cutaneous phaeohyphomycosis caused by *Alternaria alternate* and *Alternaria chlamydospora*. *J Med Vet Mycol* 1990; 28: 275.
22. Romano C, Paccagnini E, Difonzo EM. Onychomycosis caused by *Alternaria* spp. In Tuscany, Italy from 1985 to 1999. *Mycoses* 2001; 44: 73-6.
23. Glowacka A, Wasowska-Krolikowska K. Childhood onychomycosis: alternariosis of all ten fingernails. *Cutis* 1998; 62 (3): 125-8.
24. Wadhvani K, Srivatava AK. Some cases of onychomycosis in North India in different working environment . *Mycopathologia* 1985; 92: 149-55.
25. Weitzman I, Summerbell RC. The dermatophytes. *Clin Microbiol Rev* 1995; 8; 240-59.
26. Hilmioglu-Polat, S, Metin DY, Inci R, Kilinc I, Tumbay E. Non-Dermatophytic molds as agents of onychomycosis in Izmir, Turkey – a prospective study. *Mycopathologia* 2005; 160: 125-8.
27. Batawi MME, Arnaot H, Shoeib S, Bosseila M, Fangary ME, Helmy AS. Prevalence of Non Dermatophyte molds in Patients with Abnormal nails: *Egyptian Dermatology Online Journal* 2006; 2 (1): 11.
28. Bokhari MA, Hussain I, Jahnagir M, Haroon TS, Aman S, Khurshid K. Onychomycosis in Lahore, Pakistan. *Int J Dermatol* 1999; 38 (8): 591-5.

29. Hafidah RR, Abdulmir AS. Cladosporium spp. a causative agent of white superficial onychomycosis. *WHO EMRO* 2008; 14(1): 1-4.
30. Negroni R, Arechavala A, Bonvehi P. Non dermatophyte mycelia fungi in onychodystrophies. Experience of private medical center in the City of Buenos Aires. *Dermatol Argent* 2008; 14 (2): 118-123.
31. AnandanV, Nayak V, Sundaram S, Srikanth P. An Association of *Alternaria Alternate* and *Scopulariopsis Brevicaulis* in Cutaneous Phaeohyphomycosis. *Indian J Dermatol Venerol Leprol* 2008; 74 (3): 244-47.
32. Ghannoum MA, Hajjeh RA, Scher R, Konnikov N, Gupta AK, Summerbell R, *et al* . A large-scale North American study of fungal isolates from nails: The frequency of onychomycosis, fungal distribution and antifungal susceptibility patterns. *J Am Acad Dermatol* 2000; 43: 641-8.
33. English MP. Comment. Nails and fungi. *Brit J Dermatol* 1998; 94: 481-90.
34. Tosti A, Piraccini BM, Lorenzi S. Onychomycosis caused by non dermatophytic molds: *J Am Acad Dermatol* 2000; 42: 217-224.
35. Bonifaz A, Angular CP, Ponce RM. Onychomycosis by molds. Report of 78 cases. *Eur J Dermatol* 2007; 17 (1): 70-2.
36. Ikram A, Husain W, Satti ML, Wiqar MA. Invasive infection in a young immuno compitent soldier by *Scytalidium dimidiatum*. *J Coll Physician Surg Pak* 2009; 19(1):6.
37. Vásquez-del Mercado E, Arenas R. Onychomycosis among children. A retrospective study of 233 Mexican cases. *Gac Med Mex* 2008 Jan-Feb; 144(1): 7-10.
38. Ng KP, Soo Hoo TS, Nik SL, Ang LS. Dermatophytes isolated from patients in University Hospital, Kuala Lumpur, Malaysia. *Mycopathologia* 2002; 155(4): 203-6

Contribution of Authors

Umme Farwa: conception, designing,, planning experimentation manuscript writing

Wajiha Farooq: conception, designing, planning analysis interpretation discussion

Asim Saeed: experimentation study design analysis

conception, designing,, planning manuscript writing

Shagufta Hussain: Analysis interpretation discussion

manuscript writing and manuscript writing